

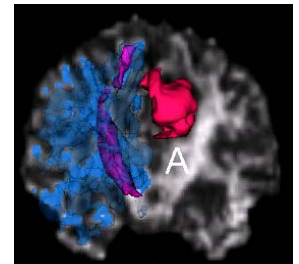
# THE EFFECT OF BEVACIZUMAB ON NORMAL APPEARING WHITE MATTER FIBERS: A DIFFUSION TENSOR IMAGING (DTI) STUDY

M. Artzi<sup>1,2</sup>, D. T. Blumenthal<sup>2,3</sup>, F. Bokstein<sup>2,3</sup>, B. W. Corn<sup>2,4</sup>, P. Mika<sup>1</sup>, O. Aizenstein<sup>5</sup>, and D. Ben Bashat<sup>1</sup>

<sup>1</sup>The Wohl institute for Advanced Imaging, Brain Imaging Center, Tel Aviv Sourasky Medical Center, Tel-Aviv, Israel, <sup>2</sup>Sackler Faculty of Medicine, Tel-Aviv University, Tel-Aviv, Israel, <sup>3</sup>Neuro-Oncology Service, Oncology Division, Tel Aviv Sourasky Medical Center, Tel-Aviv, Israel, <sup>4</sup>Radiation Oncology Unit, Oncology Division, Tel Aviv Sourasky Medical Center, Tel-Aviv, Israel, <sup>5</sup>Department of Radiology, Tel Aviv Sourasky Medical Center, Tel-Aviv, Israel

**Background / Aims:** Postoperative radiation therapy (RT) with alkylating chemotherapy (aCTr) is established first-line treatment for patients with Glioblastoma (GB)<sup>1</sup>. The combination of antiangiogenic drugs with aCTr has become a routine second-line therapy for salvage treatment of recurrent/progressive malignant glioma (rGB). Whereas the effects of radiation on the brain tissue are well characterized<sup>2</sup>, the effects of antiangiogenic drugs such as bevacizumab combined with aCTr such as Temozolomide/Irinotecan on the normal appearing brain tissue, are less known. The aim of this study was to evaluate the effect of bevacizumab and aCTr on the integrity of the normal appearing white matter (NAWM) fibers in patients with GB, using diffusion tensor imaging (DTI).

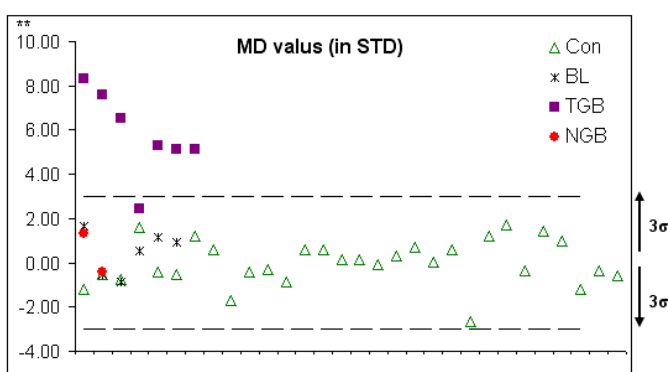
**Methods:** The control group included 31 healthy subjects. The study group included 16 patients: (I) 7 patients with GB scanned after RT, before and during the course of antiangiogenic therapy (total of 24 MR scans); (II) one patient with GB scanned longitudinally, both during RT and later during antiangiogenic therapy (total of 9 MR scans); (III) two newly-diagnosed patients with GB scanned before surgery; and (IV) 6 patients with benign brain lesions scanned before surgery. MRI scans were performed on a 3T GE scanner. DTI was performed using GE-EPI sequence with  $b=1000 \text{ sec/mm}^2$  and 15 diffusion directions. Mean values of fractional anisotropy (FA), mean diffusivity (MD), radial (Dr) and axial (Da) diffusivity were calculated from all major fibers of the entire brain and on the corticospinal tracts (CST) (Figure 1). Analysis was performed using FSL. Values were calculated from both hemispheres in the control group and only on the contra-lateral side to the lesion in tumor patients. The distance was calculated in standard deviations, between the mean values obtained in each patient and the mean normal values.



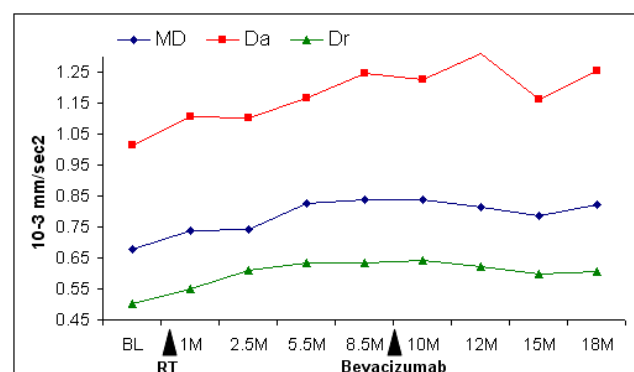
**Figure 1:** VOIs obtained from a 35yo patient with GB. Lesion - pink; CLS major fibers - blue; CST -violet.

**Results and Discussion:** *Post radiation effects:* Increased MD, Da and Dr were detected in 7/8 patients who received RT previously to the MRI scan (group I) in the major white matter fibers and in the CST (Figure 2). The one patient who had normal values was scanned two years following RT. These values were also negatively correlated between the time intervals from the end of the RT with MD ( $r=-0.83$ ,  $p=0.02$ ) and with Dr ( $r=-0.80$ ,  $p=0.03$ ). No differences were found in FA values in group I and in all diffusivity values in all other patients compared to normal values (groups II-IV, Figure 2). These results support previous reports of early and late radiation effects on the brain tissue<sup>3</sup>.

*Antiangiogenic therapy effects:* In general, no changes in diffusivity values were detected during bevacizumab and aCTr. Improvement in MD, Da and Dr was detected in 3/7 patients in group I, presumably related to brain recovery from the RT. In group II, longitudinal changes were detected following RT with increases in MD, Da and Dr parameters. While Dr and MD stabilized already after 5.5 months with slight reductions seen later, Da continued to increase (Figure 3). During bevacizumab treatment, no additional reduction in Dr and/or MD was detected.



**Figure 2:** MD values obtained from all subjects; healthy (Con - $\Delta$ ); patients with benign brain lesions (BL-x); GB after chemo/RT, before bevacizumab therapy (TGB- $\blacksquare$ ); newly diagnosed GB (NGB- $\bullet$ ); \*\* Values in std



**Figure 3:** Longitudinal changes in MD, Da and Dr during RT and during bevacizumab and aCTr. BL-baseline;M-months.

**Conclusion:** In this study, we present diffusivity changes in the NAWM during therapy with bevacizumab and aCTr presumably related to post-radiation changes. Findings of this study do not indicate additional effects of bevacizumab and aCTr therapy on diffusivity indices in the contra-lateral hemisphere. These results may have important clinical implications regarding the use of bevacizumab-related therapies in the upfront setting for glioblastoma.

**References:** <sup>1</sup>Mason et al. Curr Oncol 2007, <sup>2</sup>Kim et al. J Neurooncol 2008 <sup>3</sup>Nagesh et al., Int J Radiat Oncol Biol Phys 2008