

Differentiation of Radiation-Injuries and Tumor Recurrence Using Perfusion-weighted imaging

Y. wang¹, and L. ma²

¹department of radiology, PLA general hospital, China, People's Republic of, ²department of radiology, PLA general hospital, beijing, beijing, China, People's Republic of

The differentiation of progressive or recurrent brain tumor from radiation injury after radiotherapy is difficult using conventional MR imagings(MRI) [1]. Accurate diagnosis of tumor recurrent or radiation injury is critical to determining therapy [2]. Perfusion-sensitive contrast-enhanced MR imaging(PWI), which has made it possible to obtain measurements of vascularity within brain lesions, may be useful in differentiation of tumor recurrence within irradiated lesions and radiation necrosis [3]. Our aim was to evaluate the PWI in the characterization of newly developed enhancing lesions within irradiated regions after the treatment of brain tumor.

Methods: The PWI were obtained with a gradient-echo echo-planar (GE-EPI) technique with a readout bandwidth = 250kHz, acquisition matrix = 128 x 128, slice thickness = 6mm, FOV = 24cm, TR = 1500ms, TE = 11.4ms, 60 phases and 20 slices per phase. 15 patients with previously resected and irradiated glioma were included whose final determination was decided either histologically or clinicoradiologically(8 recurrence and 7 irradiated necrosis). Calculate the normalized rCBVratios (rCBV[enhanced]/rCBV[contralateral tissue]), the region of interest(ROIs) consisting of 20-40 pixels were located in the enhanced areas on the contrast-enhanced T1-weighted images. Whenever possible, the ROI of normal white matter was placed contralateral to the ROI of enhanced region in the same transaxial plane, the same did rCBF and MTT ratios. Mann-Whitney test was used to determine whether there was a difference in the rCBV/rCBF/MTT ratios between the patients with tumor recurrence and irradiated necrosis. Significance was set to a *P* value of < 0.05.

Results: The PWI parameters (rCBV/rCBF/MTT ratios) of tumor recurrence group and irradiated necrosis group are different. the rCBV ratios of tumor recurrence group is 2.80 ± 1.62 , while the irradiated necrosis group is 0.86 ± 0.70 . the rCBF ratios of tumor recurrence group is 2.18 ± 1.14 , while the irradiated necrosis group is 0.95 ± 0.93 (Fig.1/2/3). The differences of these two parameter(rCBV/rCBF ratios) between the two groups reached statistical significance(*P* =0.011 and 0.037). The area of under rCBV and rCBF ROC curve was 0.893 and 0.821(Fig.4). The sensitivity and specificity of the two parameter between tumor recurrence group and irradiated necrosis group are stasticed.

group		rcbv	rcbf	mtt
recurrence	Mean	2.80	2.18	1.26
	Std.	1.62	1.14	.32
necrosis	Mean	.86	.95	.99
	Std.	.70	.93	.32

Fig.1 two groups PWI parameters Mean and Std. Deviation.

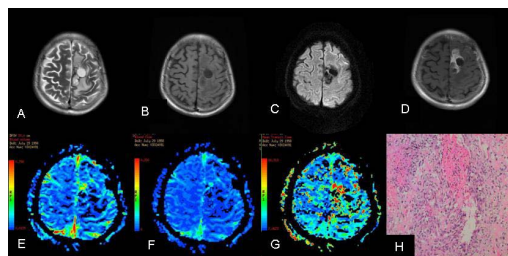


Fig.2 50-year-old woman with recurrent glioma verified by surgical resection. A-D, Conventional MR scan showed left frontal lobe focally enhancing lesion. E, rCBV maps appears as hypervascularity (rCBV ratios =6.39). F-G, rCBF/MTT maps H, pathological image.

parameter		Under curve area
rCBV	Mean	.893
	Std.	.086
rCBF	Mean	.821
	Std.	.121

Fig. 4 The area of under rCBV and rCBF ROC curve

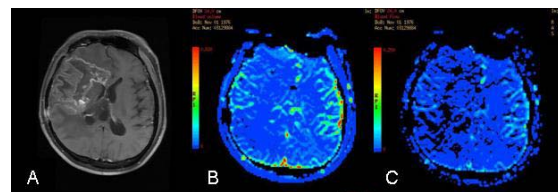


Fig.3 32-year-old man with radiation necrosis verified by follow up. A, Contrast-enhanced T1-weighted MR image. B, rCBV maps the enhancing lesion shows hypovascularity(rCBV ratios =1.49). C,rCBF maps.

Conclusions: Both the normalized rCBV and rCBF ratios of the tumor recurrence group were higher than those of the radiation-injuries group. Perfusion-weighted imaging should be the prior choice in distinction of radiation-injuries and tumor recurrence. The ratios of rCBV and rCBF has important clinical value in differentiating them.

References:

- [1] Schlemmer HP, *et al.* *Neuroradiology*, 2002, 44: 216-222.
- [2] Soonmee Cha. *TMRI*, 2004, 15: 279-289.
- [3] Takeshi S. *AJNR*, 2000, 21: 901-909.