

Widespread and Different Distribution of Extrafocal NAA/(Cr+Cho) Reductions in Mesial Temporal Lobe Epilepsy (TLE) with and without Mesial Temporal Sclerosis

S. G. Mueller¹, A. Ebel¹, J. Barakos², C. Scanlon¹, I. Cheong¹, D. Finaly¹, P. Garcia³, M. W. Weiner¹, and K. D. Laxer²

¹Dept. of Radiology and Biomedical Imaging, UCSF, Center for Imaging of Neurodegenerative Diseases, San Francisco, CA, United States, ²Pacific Epilepsy Program, California Pacific Medical Center, ³Department of Neurology, UCSF

Introduction: Mesial temporal lobe epilepsy (TLE) is the most common form of partial epilepsy. Based on imaging and histopathological findings two types of non-lesional medial TLE are distinguished: a. TLE with mesial-temporal lobe sclerosis on MRI (TLE-MTS) and b. TLE with normal appearing MRI (TLE-no). Using multiple single voxel spectroscopy or multiple slice spectroscopic imaging techniques, it has been shown that NAA reductions are not restricted to the focus in TLE but are also found in extrahippocampal and even extratemporal regions. Due to the limited brain coverage these previous studies were not able to conclusively assess differences of distribution and/or extent of extrafocal NAA reductions between TLE-MTS and TLE-no. Using a whole brain 3D echoplanar spectroscopic imaging sequence (EPSI) the following specific aims were addressed. 1. To confirm the findings of previous studies showing that extrahippocampal/extratemporal NAA reductions exist in unilateral TLE. 2. To test if TLE-MTS and TLE-no differ regarding distribution and severity of these abnormalities. 3. To test, if severity and extent of extrahippocampal NAA reductions provide additional information for focus lateralization in TLE-MTS or TLE-no.

Methods: 14 TLE-MTS (mean age $39.7.3 \pm 12.9$; left TLE/right TLE: 6/8) and 14 TLE-no (mean age 37.9 ± 7.9 ; left TLE/right TLE: 7/7) and 18 healthy volunteers (mean age 33.5 ± 10.0) were studied on a 4T Bruker MedSpec system and the following sequences acquired. 1. Volumetric T1-weighted gradient echo MRI (MPRAGE) TR/TE/TI = 2300/3/950 ms, $1.0 \times 1.0 \times 1.0 \text{ mm}^3$ resolution for segmentation in gray, white and CSF maps. 2. 3D whole brain EPSI TR/TE/TI=1780/45/280 ms, FOV=280x280x180 mm^3 . Metabolite and water reference data were acquired in an interleaved fashion. The spectroscopic imaging data/water reference data was reconstructed and fitted. NAA/(Cr+Cho) maps were derived from the resulting metabolite maps. The T1 image was co-registered to the water reference data and the resulting image was spatially normalized to a customized symmetrical template with lobe markings. The thus derived transformation matrices were applied to the NAA/(Cr+Cho) map and the co-registered gray matter map. Mean lobar NAA/(Cr+Cho), mean lobar gray matter and % of the lobe covered by EPSI were calculated for each subject. Multiple linear regression analysis with lobar NAA/(Cr+Cho) weighted for lobar coverage as dependent variable and age and mean gray matter as nuisance variables was used to assess differences of mean lobar NAA/(Cr+Cho) between the three groups. SPM2 was used to identify regions with significant NAA/(Cr+Cho) reduction (cluster) in individual TLE patients by comparing them with the control group (1 scan/subject, t-test).

Results: Compared to controls TLE-MTS and TLE-no had widespread extrahippocampal NAA/(Cr+Cho) reductions. NAA/(Cr+Cho) abnormalities had a temporal-occipital distribution in TLE-MTS and a frontal-temporal distribution in TLE-no (cf. Figure 1). TLE-MTS and TLE-no were not different from each other regarding severity of these NAA/(Cr+Cho) reductions. 5 TLE-MTS and 5 TLE-no had no clusters with significant NAA/(Cr+Cho) reductions. The remaining 9 TLE-MTS had 1 – 5 clusters with abnormally low NAA/(Cr+Cho) (average number (No) of clusters: 2.9, average cluster size: 24075.3 voxels; average size of largest cluster: 81047.3 voxels). The remaining 9 TLE-no had 1 – 7 clusters with abnormally low NAA/(Cr+Cho) (average No of clusters: 3.2; average cluster size: 3257.0 voxels; average size of largest cluster: 4795.2 voxels). When arbitrarily defining the region with the largest cluster of reduced NAA/(Cr+Cho) as the “focus determined by 3D EPSI”, EPSI correctly identified the epileptogenic temporal lobe in 5 TLE-MTS but in none of the TLE-no.

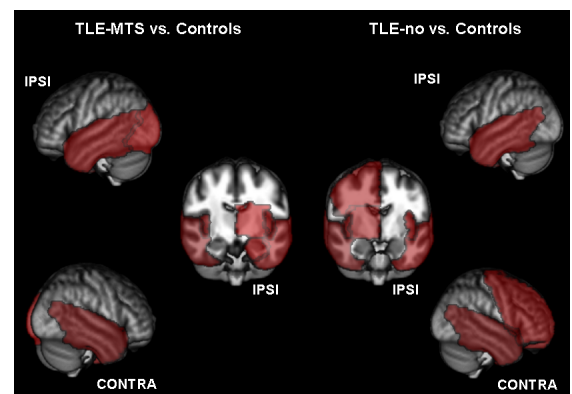


Figure 1: Lobes with significantly reduced NAA/(Cr+Cho) highlighted in red.

Conclusion: This study confirmed findings of widespread extrafocal NAA/(Cr+Cho) abnormalities in TLE-MTS and TLE-no described by previous spectroscopic imaging studies with partial brain coverage. The finding that extrafocal NAA/(Cr+Cho) reductions show a considerable individual variation in extent and severity within each of the subtypes demonstrates that a homogeneous pattern of neuronal dysfunction/neuronal loss does not exist in either TLE-MTS or TLE-no. Furthermore, the different distribution of the NAA/(Cr+Cho) abnormalities compared to TLE-MTS suggests that TLE-no is a distinct TLE entity. Further studies will be necessary to obtain a better understanding of the nature of these metabolic abnormalities and of their influence on cognitive performance and long term outcome after epilepsy surgery.