

The In-Vivo Topographical Distribution of Brain Tissue Loss Associated With Depression in Parkinson's Disease: A Voxel-Based Morphometry Study

M. Filippi¹, F. Agosta¹, I. Petrovic², S. Galantucci¹, V. Spica², M. Jecmenica², and V. Kostic²

¹Neuroimaging Research Unit, Institute of Experimental Neurology, Division of Neuroscience, Scientific Institute and University Hospital San Raffaele, Milan, Italy, ²Department of Neurology, School of Medicine, University of Belgrade, Belgrade, Yugoslavia

Introduction: Depression in Parkinson's disease (PD) is likely to depend on damage to distributed neuronal networks consisting of cortical and limbic regions rather than on dysfunction of a discrete brain region. In this study, we investigated, using MRI and voxel-based morphometry (VBM), whether specific patterns of gray (GM) and white matter (WM) tissue loss are associated with depression in patients with PD.

Methods: Brain MRI was obtained in 40 PD patients and 26 healthy subjects. Patients were diagnosed as having depression using the DSM-IV criteria. The Hamilton rating scale for depression (HDRS) was administered to all patients. The topographical distribution of brain tissue loss in PD patients and controls was assessed using VBM as implemented in the Statistical Parametric Mapping (SPM5) and the Diffeomorphic Anatomical Registration using Exponentiated Lie algebra method (DARTEL).

Results: Twenty-four PD patients were diagnosed as non-depressed (PD-NDep) and 16 as having depression (PD-Dep). The two patient groups were similar in terms of clinical findings, except for the HDRS score ($p < 0.001$). Compared to controls, all PD patients showed GM loss in the right anterior cingulate (AC) cortex and insula, and in the left middle frontal and angular gyri ($p < 0.001$). No regions of WM loss common to PD-NDep and PD-Dep patients relative to healthy controls were found. PD-Dep patients vs. PD-NDep showed WM loss in the right AC bundle and inferior orbitofrontal (OF) region ($p < 0.001$). In PD patients, HDRS score correlated significantly with WM loss in the right inferior OF region ($r = -0.51$, $p < 0.05$).

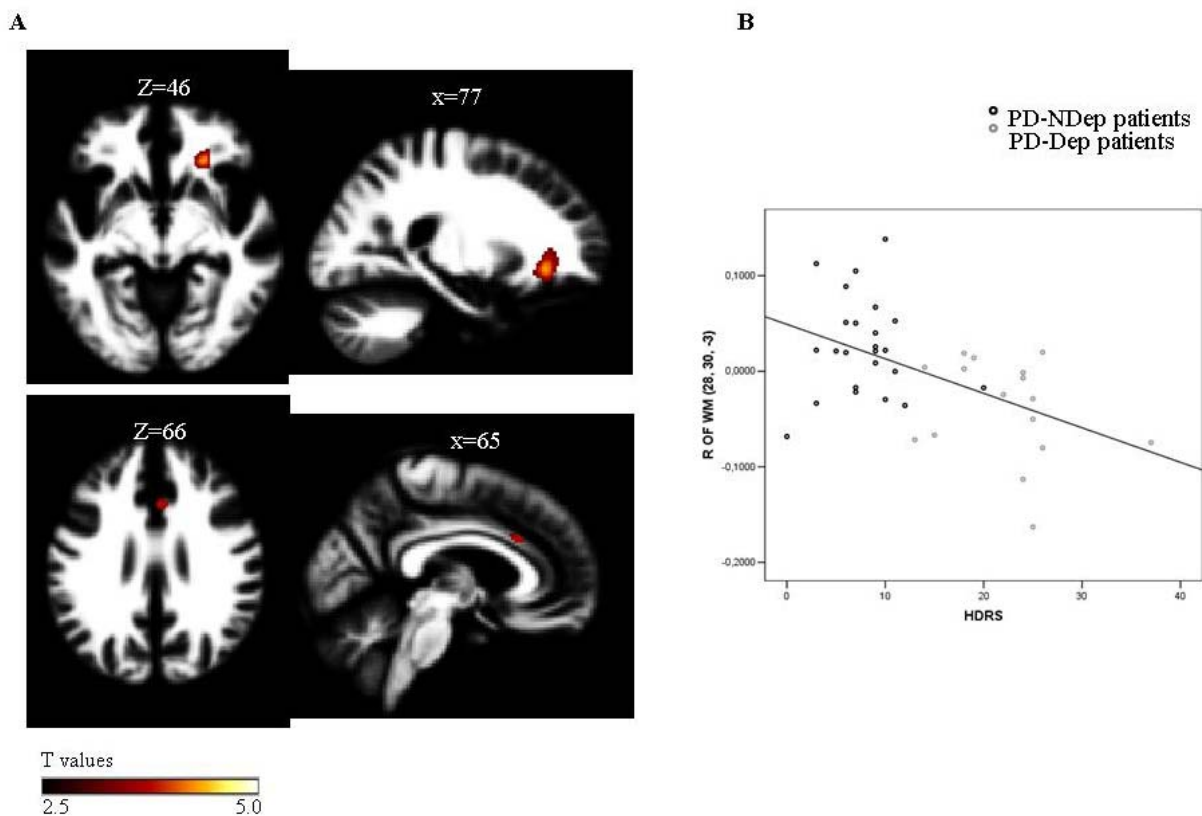


Figure. (A) WM regions more atrophic in PD-Dep compared to PD-NDep are superimposed on representative sagittal and axial slices of the customized WM template, at a threshold of $p < 0.001$ uncorrected. (B) Scatterplot of the correlation between the HDRS score and the right inferior OF WM in all PD patients ($r = -0.51$, $p < 0.05$ corrected).

Conclusions: Significant tissue loss in several WM regions within the cortical-limbic network occurs in PD-Dep vs. PD-NDep patients. Such a pattern of brain atrophy overlaps with the key regions involved in major depressive disorders, suggesting an increased vulnerability of this neural circuit in PD. This may partially account for the high prevalence of depression in PD.