

The Topographical Distribution of White Matter Damage in Parkinson's Disease and Progressive Supranuclear Palsy

F. Agosta¹, S. Galantucci¹, T. Stojkovic², A. Tomic², I. Petrovic², G. Longoni¹, V. Kostic², and M. Filippi¹

¹Neuroimaging Research Unit, Institute of Experimental Neurology, Division of Neuroscience, Scientific Institute and University Hospital San Raffaele, Milan, Italy,

²Department of Neurology, School of Medicine, University of Belgrade, Belgrade, Yugoslavia

Introduction. Progressive supranuclear palsy (PSP) is the second most common cause of neurodegenerative-parkinsonism after idiopathic Parkinson's disease (PD) [1]. A different ante-mortem distribution of white matter (WM) damage may exist in PD and PSP patients, which might be helpful in the diagnostic work-up of these patients [2]. In this study, we investigated microstructural changes of WM in patients with PD and different PSP syndromes using tract-based spatial statistics (TBSS).

Methods. Brain conventional and diffusion tensor (DT) MRI was obtained in 20 PSP patients (mean age: 65; mean the Unified Parkinson's Disease Rating Scale (UPDRS) III: 32.8), 39 PD patients (mean age 66, mean UPDRS III: 20.4), and 26 age- and sex-matched healthy subjects (mean age: 63). PSP patients were classified as Richardson's syndrome (PSP-RS, 10 patients) or PSP-Parkinsonism (PSP-P, 10 patients) based on clinical criteria [3]. TBSS analysis was performed using FMRIB's Diffusion Toolbox [4] to compare fractional anisotropy (FA) values between groups.

Results. Compared with controls and PD patients, PSP-RS patients had areas of significantly decreased FA in the superior cerebellar peduncle (SCP), the cerebral peduncle, the pontine commissural WM, as well as in multiple supratentorial areas including corpus callosum, middle cingulum, corona radiata, internal capsulae, fornix, and fronto-parietal WM ($p < 0.05$, corrected for multiple comparisons). In all these regions, FA was also decreased in PSP-RS vs. PSP-P patients ($p < 0.001$, uncorrected) (Figure).

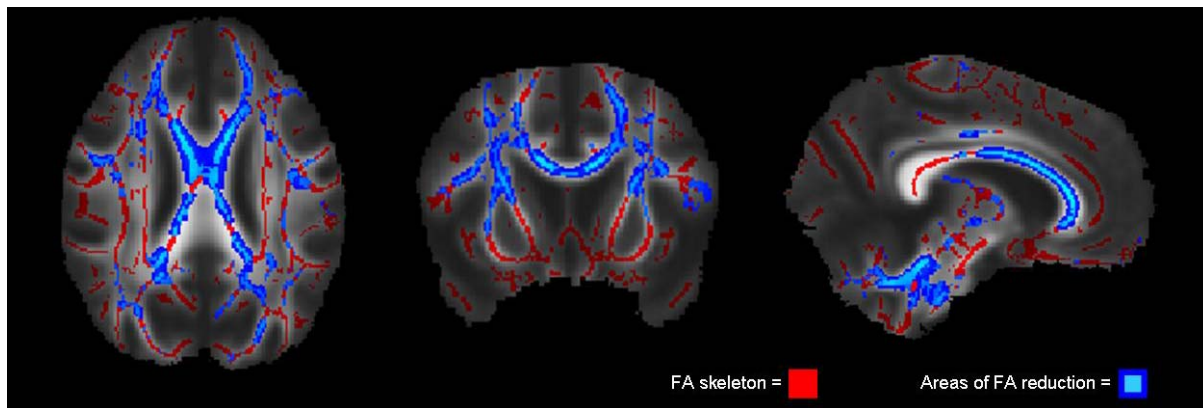


Figure. Pattern of significant FA decrease (in blu) in patients with Richardson's syndrome (PSP-RS) compared with patients with Parkinson's disease. The FA skeleton is represented in red. Results are displayed on the mean FA map.

A similar pattern of FA decrease (except for the SCP) was found when PSP-P patients were compared with controls and PD patients, but only at a less stringent level of significance ($p < 0.001$, uncorrected). No regions of decreased FA were found comparing PSP-P vs. PSP-RS patients.

Conclusions. This study suggests impaired structural integrity affecting WM tracts in PSP patients but not in PD. In keeping with pathological data, WM microstructural damage was more pronounced in PSP-RS vs. PSP-P patients. The less prominent involvement of WM in PSP-P patients might be associated to their favorable clinical status.

References.

- [1] Litvan I, Agid Y, Calne D, et al. *Neurology* 1996;47:1-9.
- [2] Rizzo G, Martinelli P, Manners D, et al. *Brain* 2008;131:2690-2700.
- [3] Smith SM, Jenkinson M, Johansen-Berg H, et al. *NeuroImage* 2006;31:1487-1505.
- [4] Williams DR, de Silva R, Paviour DC, et al. *Brain* 2005;128:1247-1258.