

## Early and Late Onset Alzheimer's Disease Patients Have Distinct Patterns of White Matter Damage

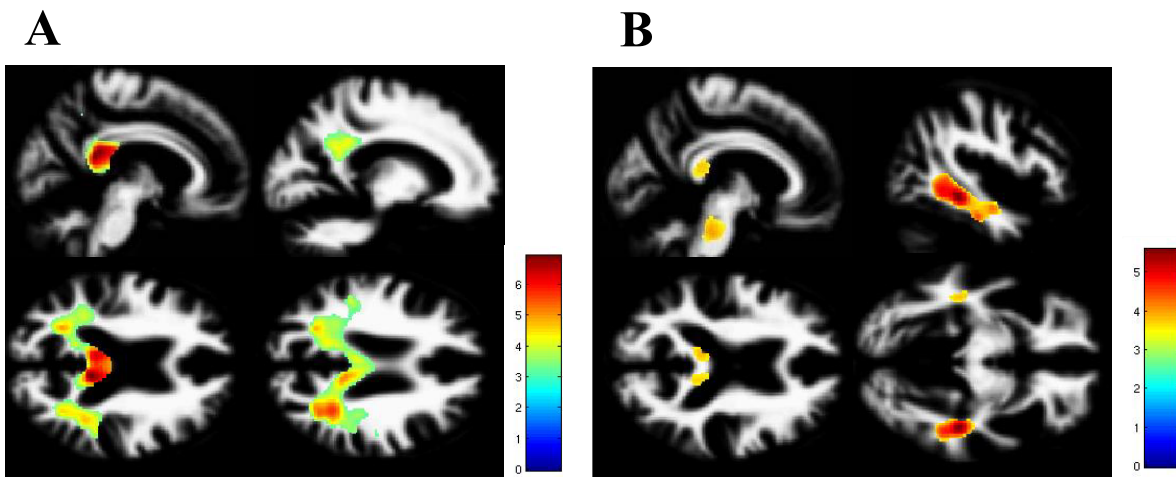
E. Canu<sup>1</sup>, F. Agosta<sup>1</sup>, M. Pievani<sup>1,2</sup>, G. B. Frisoni<sup>3</sup>, and M. Filippi<sup>1</sup>

<sup>1</sup>Neuroimaging Research Unit, Institute of Experimental Neurology, Division of Neuroscience, Scientific Institute and University Hospital San Raffaele, Milan, Italy, <sup>2</sup>LENITEM, IRCCS S.Giovanni di Dio, Fatebenefratelli, Brescia, Italy, <sup>3</sup>LENITEM, IRCCS Centro San Giovanni di Dio - Fatebenefratelli IRCCS Centro San Giovanni di Dio, Fatebenefratelli, Brescia, Italy

**Introduction.** While Alzheimer's disease (AD) has been often considered a disease of gray matter (GM), recent studies have provided evidence of white matter (WM) volume loss in the corpus callosum, the parahippocampal areas, and the cingulum from AD patients. The classification of AD into subtypes based on the time of onset of symptoms (before or after age of 65 years) is still controversial. Compared to late onset (LOAD), early onset AD (EOAD) patients show a different clinical pattern: a faster cognitive deterioration where the memory complaints could be secondary to language impairment or other neocortical functions. Moreover, EOAD show more GM atrophy in the parietal and temporal regions. On the contrary, LOAD shows a predominant medial temporal lobe involvement. The patterns of WM loss in LOAD and EOAD have never been investigated. Aim of this study is to define the patterns of WM volume loss in patients with EO and LOAD compared to healthy controls (HC).

**Methods.** Fourteen EOAD patients (65 year old or younger at disease onset) and 15 LOAD patients (onset after age 65 years) were studied. Patients were matched for dementia severity and for years of disease duration. Thirty age- and sex-matched HC were also recruited (15 younger and 15 older). All participants underwent an MRI scan. The Statistical Parametric Mapping (SPM5) and the Diffeomorphic Anatomical Registration using Exponentiated Lie algebra method (DARTEL) were used to perform a voxel-based morphometry (VBM) analysis. Analyses of covariance were performed to assess WM differences in all AD patients vs. HC, and in EOAD and LOAD, separately, vs. age-matched HC.

**Results.** Compared to HC, AD patients showed WM loss in the parahippocampal regions, posterior cingulum bundle, splenium of the corpus callosum, fornix, and the lateral parietal regions, bilaterally. In EOAD patients, WM loss was mapped mainly to the posterior regions such as the posterior cingulum and the lateral parietal regions, bilaterally (Figure A). In LOAD patients, WM loss was confined to the medial temporal lobe in the parahippocampal regions (Figure B).



**Figure A:** comparison between EOAD and matched HC. **Figure B:** comparison between LOAD and matched HC. T bars represent T-values. Contrasts are displayed on the WM DARTEL template which is representative of the considered sample. The results are shown at  $p < .05$  corrected for FDR.

**Conclusions.** Our findings indicate that EOAD and LOAD patients differ in the topography of WM damage, which reflects the pattern of cortical loss.