

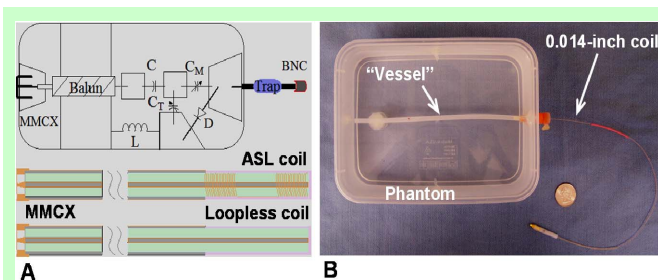
# Development of a 0.014-inch anti-solenoid loop coil: Toward intracoronary 3.0T MRI and interventions

H. Gu<sup>1</sup>, F. Zhang<sup>1</sup>, Y. Meng<sup>1</sup>, B. Qiu<sup>1</sup>, and X. Yang<sup>1</sup>

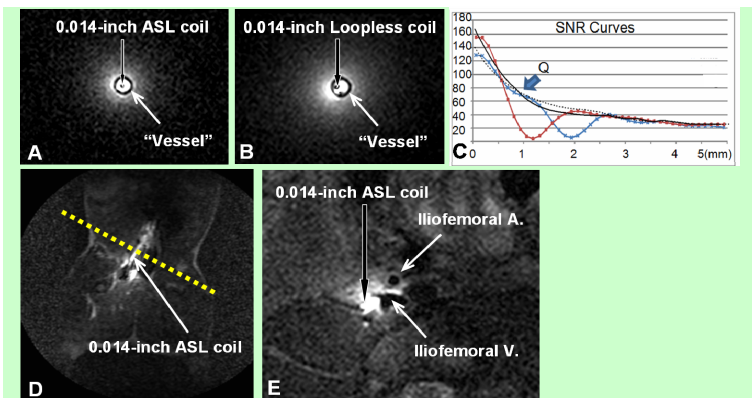
<sup>1</sup>Image-Guided Bio-Molecular Intervention Researchers, Department of Radiology, Institute for Stem Cell and Regenerative Medicine; University of Washington School of Medicine, Seattle, Washington, United States

**PURPOSE:** Atherosclerotic coronary artery disease is the main cause of heart attack. Unlike plaques in carotid arteries, the atherosclerotic plaques in coronary arteries are difficult to be detected using conventional MRI techniques with surface coils. To solve this problem, a 0.014-inch intracoronary MR imaging-guidewire (a loopless RF coil) was invented, which enabled to generate intracoronary MRI at 1.5T and interventions under MRI guidance [1]. In this study, we attempted to develop a 0.014-inch anti-solenoid loop coil, an alternative to the loopless coil which might be used for generating intracoronary high-resolution 3.0T MRI and interventions.

**METHODS:** We first designed two intracoronary coils of (i) a loopless coil (antenna) and (ii) an anti-solenoid loop (ASL) coil. The ASL coil consisted of two solenoids, each of which was made with 20 turns of 50-AWG enameled copper wires. The two coils had the same characteristic parameters, including the 0.014-inch diameter of coaxial cables (Microstock, West Point, PA), 16 inch in length, 1.6-inch long tips with 100 Q factor that was tuned with a network analyzer (Agilent Technologies, Santa Clara, CA)(Fig. 1A). The tuning boxes of two 0.014-inch coils had the same circuit structure. To test the functions of the two coils, we performed in vitro experiments by placing each of two coils into a “vessel” (a plastic tube) that was positioned into a phantom (a plastic box filled with 0.9% sodium chloride solution)(Fig. 1B). The coils were connected through a custom-designed preamp box to a clinical 3.0T MRI scanner (Achieva, Philips Healthcare, Best, Netherlands). To compare the image SNRs and penetration between two 0.014-inch coils, we used a turbo spin echo (TSE) sequence for axial and sagittal T2-weighted images (T2WI) of the “vessel” with TR=4000ms, TE=60ms, TSE factor=6, FOV=60mm×60mm, slice thickness=1mm, slice gap=1mm, matrix=120×114, and NSA=4. Then, SNRs and penetration curves from the two coils to the radial outer sides were calculated by a custom designed program. To validate the feasibilities for intravascular 3.0T MRI, we placed the ASL coil into the iliofemoral vein of a living pig and then generated intravenous MRI of its parallel-running iliofemoral artery.



**Fig. 1.** (A, upper) Schematic diagram of the tuning box for both 0.014-inch ASL and loopless coils. Balun and trap are added to enhance the electrical isolation and reduce the system interference.  $C_T$  and  $C_M$  are variable capacitors for tuning coils Q factors to 100 and matching system resistance to 50ohm at 127.72MHz. (lower) Mechanical structures of the ASL coil and the loopless coil, which are connected to the tuning box by a MMCX connector. (B) In vitro experimental setting up with a phantom.



**Fig. 2.** (A&B) In vitro axial T2WI with the ASL coil (A) compared to the loopless coil (B). (C) SNR curves for the ASL coil within the “vessel” (red line) and without the “vessel” (black line), as well as for the loopless coil within the “vessel” (blue line) and without the “vessel” (thin dash line). (D) In vivo scout MRI at the coronal view to localize the intravenously-placed ASL coil, crossing which an axial intravenous 3.0T T2WI of the parallel-running iliofemoral artery is achieved (E).

**RESULTS:** Both 0.014-inch coils could function with the clinical 3.0T MR scanner (Fig. 2A&B). Fig. 2C presents the SNR curves of the two coils, showing the Q point (the intersection of the lines of two coils), which indicates higher SNR within 1mm radius with the ASL coil than that with the loopless coil. However, the loopless coil had greater penetration than the ASL coil. In vivo MRI demonstrated that ASL coil could be used to generate intravascular 3.0T MRI without disturbance by low blood flow in the iliofemoral vein.

**Conclusions:** This study demonstrates the initial development of a 0.014-inch ASL coil, which may become an alternative to 0.014-inch loopless coil for intracoronary 3.0T MRI and interventions.

**Acknowledgments:** This study was supported by an NIH R01 HL078672 grant.

**References:** [1] Qiu B, et al. *Magn Reson Med*; 2005: 986.