

MR GUIDED TRANSMYOCARDIAL DELIVERY OF HEPATOCYTE GROWTH FACTOR GENE INTO INFARCT SCAR WITH ESTABLISHED REMODELLED LEFT VENTRICLE

M. Saeed¹, D. Saloner¹, P. Ursell², L. Do¹, M. Wilson¹, and A. J. Martin¹

¹Radiology and Biomedical Imaging, University of California San Francisco, San Francisco, Ca, United States, ²Pathology, University of California San Francisco, San Francisco, Ca, United States

Purpose

In open-chest swine model epicardial delivery of hepatocyte growth factor (HGF) gene (pCK-HGF, VM202™) into infarcted myocardium 3 days after coronary occlusion/reperfusion significantly improved LV function, perfusion and viability. It is unknown whether MR-guided transendocardial delivery of pCK-HGF is effective in ameliorating LV remodelling. This study used MR-guided active catheter technology in animals with remodelled LV to test pCK-HGF efficacy.

Methods

XMR suite (Philips, Best, The Netherlands) featuring an x-ray catheterization lab and a 1.5T MR short-bore scanner with an in-room display monitor and console for viewing and interactive scanning enable LV catheterization under real-time imaging, transendocardial catheter-based gene delivery and assessing non-invasively the gene effects. MR imaging was performed 3 days, 5 weeks after infarction (prior to therapy) and 5 weeks after therapy. Injection using the following sequences: 1) Cine MR imaging for measuring global LV and regional LV function, 2) tagged MR imaging for measuring circumferential strain and LV absolute rotation; 3) Phase-contrast velocity-encoded MR imaging for measuring longitudinal strain; 4) First-pass perfusion MR imaging for measuring relative myocardial perfusion; 5) DE-MR imaging for measuring infarct size and infarct transmural thickness and 6) MR-fluoroscopy for navigating the percutaneous endovascular catheter to the target. Swine (n=18) subjected to myocardial infarction developed LV remodelling at 5 weeks. At that time and under MR-guidance, infarct scar was injected with either pCK-LacZ (3mg, control gene) or pCK-HGF (3mg, therapeutic gene). The genes were delivered into 8 sites covering the entire scar. Hematoxylin and eosin, Masson trichrome and biotinylated *Bandeiria simplicifolia* isolectin B4 were used to confirm the formation of new blood vessels in infarct scar and measure myocyte diameter after gene delivery.

Results

Coronary occlusion/reperfusion and transendocardial gene delivery was successfully performed under X-ray and MR-guided fluoroscopy, respectively. The active endovascular catheter was useful in hitting the target, infarct scar, and delivering the genes (Fig. 1). The transendocardial delivery of pCK-HGF under MR-guidance was effective as shown by the positive changes at the global, regional and cellular levels.

At the global level, pCK-HGF gene significantly increased LV ejection fraction and decreased volumes. The pCK-LacZ and pCK-HGF groups showed no significant difference in infarct size, ejection fraction, heart rate, arterial blood pressure or LV mass prior to gene delivery.

At the regional level, cine, tagged and phase-contrast velocity-encoded, and first pass perfusion MR imaging showed significant changes in both groups at 3 days and 5 weeks after infarction. After delivery of pCK-HGF gene there were significant increase in regional function (radial, circumferential and longitudinal strain) and structure (wall thickness of the infarct at diastole (from 5.7 ± 0.5 mm at 5 weeks after infarction to 6.6 ± 0.3 mm at 5 weeks after therapy, $P < 0.05$) compared with pCK-LacZ (5.7 ± 0.4 mm to 5.4 ± 0.6 mm at diastole). These changes were associated with reduction in infarct size and transmural thickness on DE-MR imaging. Furthermore, perfusion parameters (maximum upslope, peak signal intensity and time to peak) were also improved.

At the cellular level, histopathology showed viable islands/peninsulas around newly formed blood vessels in pCK-HGF treated, but not pCK-LacZ controls (Fig. 2). The induction of angio/arteriogenesis was demonstrated on isolectin B₅. The number of vessels in infarct scar was greater in pCK-HGF treated (206 ± 10 capillaries/mm²) compared with pCK-LacZ control animals (78 ± 25 capillaries/mm², $P < 0.05$). Significant difference was also observed in the number of arterioles within the infarct scar between pCK-HGF (11.7 ± 1.9 arterioles/mm²) and pCK-LacZ controls (3.4 ± 0.5 arterioles/mm²). Myocyte diameters of remote myocardium in pCK-HGF (16.4 ± 0.8 μm) and pCK-LacZ control animals (18.3 ± 0.2 μm) were not significantly different, respectively.

Conclusion

MR-guided transendocardial delivery of hepatocyte growth factor gene a) ameliorated global function and 3D regional strain in remodelled LV, b) activated angiogenesis, arteriogenesis and myogenesis in infarct scar and improved regional perfusion and c) reduced infarct size and transmural thickness. XMR imaging has the potential to guide delivery of local therapy and monitor the progression and regression of LV remodelling. The combination of this therapy and XMR technique may be useful in patients with ischemic myocardium associated with cell loss (apoptosis).

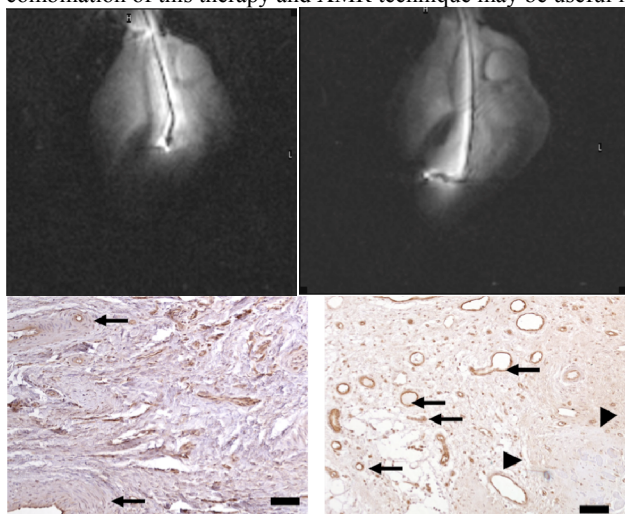


Fig. 1. MR fluoroscopic images show the navigation of the endovascular catheter in the LV chamber (left) and the injection of the gene 5 weeks after infarction (right). The images were created with signal from the catheter.

Fig. 2. Histopathological heart sections stained with isolectin B₅ after delivery of pCK-LacZ control gene (left) and therapeutic pCK-HGF gene (right). The pCK-LacZ treated animal showed few modified thick-walled blood vessels with very small lumen (arrows) embedded in scar tissue. On the other hand, the animal treated with PCK-HGF (left) showed numerous thin-walled new blood vessels (arrows). Calibration bars =50 microns.