

Max CAPR: Preliminary Clinical Studies with 5 sec Acquisition Times

C. R. Haider¹, E. A. Borisch¹, J. F. Glockner¹, P. M. Mostardi¹, and S. J. Riederer¹

¹Radiology, Mayo Clinic, Rochester, MN, United States

To capture clear arterial phases during rapid arterial to venous transit of contrast in diabetics with ulcerations of the lower leg high temporal resolution is required. Alternatively, to clearly see the morphology of tortuous collateral vessels and complex filling patterns of chronically ischemic peripheral vasculature high spatial resolution is required. The efficacy of routine clinical imaging of the lower legs should not depend on triaging patients to a number of different imaging protocols but rather ideally use a single sequence which simultaneously attains high temporal and spatial resolution without loss in diagnostic image quality. Here we describe a candidate sequence.

In this work a single phase Cartesian Acquisition with Projection-Reconstruction-like sampling (Max CAPR) is described and evaluated with three hypotheses. Hypothesis 1 (H1): Non-view-shared sequences have improved temporal fidelity as compared to similar view-shared sequences. H2: Non-view-shared sequences have improved leading edge depiction as compared to similar view-shared sequences. H3: Non-view-shared sequences provide comparable diagnostic image quality to similar view-shared sequences and peripheral run-off CTA in the calves. This is an extension of previous work [1] and denotes the first rigorous characterization and clinical application of single phase imaging with high temporal and spatial resolution to the peripheral vasculature.

Methods. *k-Space sampling:* The CAPR k-space footprint can be divided into two distinct regions: an outer annulus with one-half asymmetric sampling in vane-like patterns and a central fully sampled region [2]. In Max CAPR the number of vanes collected is reduced by sparsely sampling the outer vane sets, reducing the total acquisition time. A 3T MR imager (GE, V14.0) with an eight-element receive only array was used. Parameters used for imaging both lower legs consisted of a coronal orientation with TR/TE of 5.85/2.7 msec; flip angle 30°; BW ±62.5 kHz; FOV 40x32x13.2 cm³; sampling matrix 400x320x132. Additional acceleration parameters were partial Fourier in the outer annulus of 1.8, 2D SENSE acceleration of 8, and sparse sampling of the outer annulus from Max CAPR of 2.3 for a net acceleration of 37.7. The image update time was equal to the acquisition time per frame of 4.9 sec. A 20 ml of Gd contrast agent was injected at 3 mL/sec followed by 20 ml of saline at 3 mL/sec. The imaging sequence was initiated prior to contrast arrival and continued through late venous phase.

Experiments: All experiments were performed with the above imaging sequence. Phantom experiments were performed to assess the ability of the Max CAPR technique to portray the leading and trailing edges of a 400 mm long vial 22 mm in diameter moved along a table top track using a computer-controlled stepper motor at 16 mm/sec mimicking the advancing contrast bolus [3]. Nine volunteer studies were completed to evaluate the in vivo performance characteristics of Max CAPR. Additionally, 17 patients who underwent clinically indicated peripheral run-off CTA studies were recruited for subsequent Max CAPR examination. The studies were completed within 48 hours of the CTA with the majority occurring on the same day.

Radiological Evaluation: Results from the patient studies were reviewed by an experienced radiologist on a workstation allowing arbitrary orientated review of the source data through time and MIPs. Six evaluation criteria were rated on a four point scale with 1-poor and 4-excellent, and comparing Max CAPR to CAPR for each patient including image artifact, arterial to venous separation, vessel continuity and sharpness, leading edge quality and overall image quality. The Max CAPR results were also compared to the corresponding CTA.

Results. Phantom studies shown in Fig 1 show improved temporal fidelity for Max CAPR (C) vs. view-shared CAPR reconstructed using two different view orders (A,B). Both leading and trailing edges are sharply depicted. Fig 2a. shows a targeted A/P MIP from the peripheral run-off CTA vs. Fig. 2b the full A/P MIP of peak arterial phase of the Max CAPR exam. In Fig 2a heavy calcification is present in both popliteal arteries at the level of the anterior tibial artery origin which limits assessment of the severity of stenosis. In Fig. 2b the severe stenosis of the right popliteal artery as well as occlusion of the left popliteal artery and communicating arteries that fill the major vessels of the left calf are well seen on the Max CAPR MRA. In Fig. 2c-e the collateral arteries are seen filling the posterior tibial (PT) and peroneal (P) arteries and demonstrate isotropic spatial resolution and high vessel contrast.

Conclusion. This work represents the first technical and clinical evaluation of a non-view-shared 3D sequence capable of imaging arterial to venous transit of contrast in the ischemic peripheral vasculature with 5 sec acquisition times and 1 mm isotropic resolution. The method appears to provide some advantage over CTA with respect to insensitivity to calcium.

References. [1] Haider ISMRM 2009 #2649; [2] Haider MRM 60:749(2008); [3] Mostardi MRM 62:85(2009).

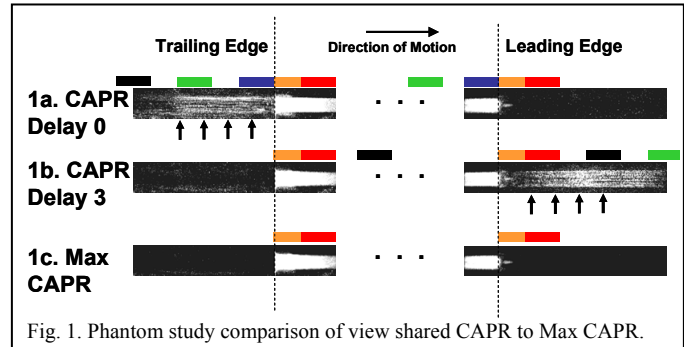


Fig. 1. Phantom study comparison of view shared CAPR to Max CAPR.

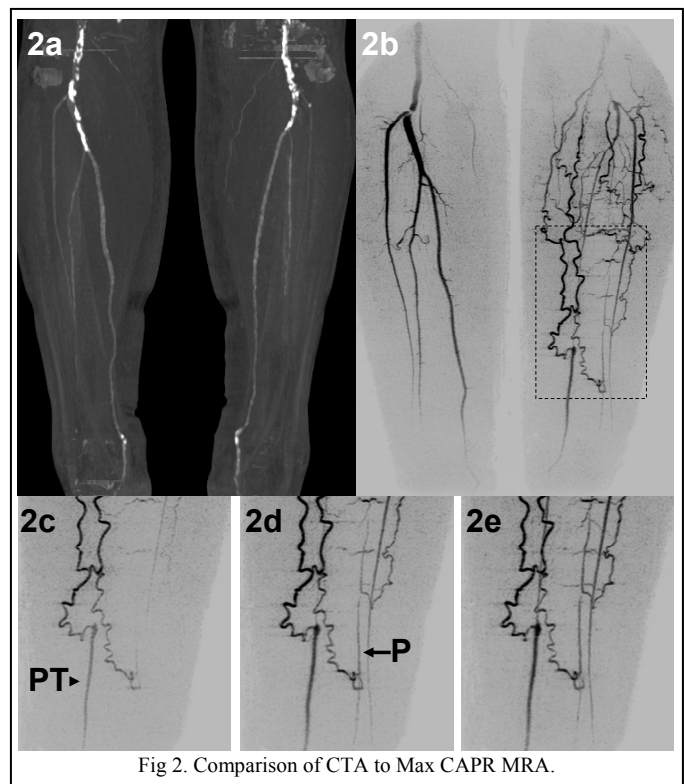


Fig 2. Comparison of CTA to Max CAPR MRA.