

Contribution of subpial pathology to cortical thinning in multiple sclerosis: a combined 7T - 3T MRI study.

C. Mainero¹, T. Benner¹, A. Radding¹, A. van der Kouwe¹, R. P. Kinkel², and B. R. Rosen¹

¹A. A. Martinos Center for Biomedical Imaging, Massachusetts General Hospital, Charlestown, MA, United States, ²Neurology, Beth Israel Deaconess Medical Center, Boston, MA, United States

Introduction. In patients with multiple sclerosis, whether cortical lesions and cortical atrophy reflect two different aspects of the same degenerative process, or have different biological substrates, has not yet been clarified. It is unclear when cortical disease is a consequence of white matter (WM) demyelination with secondary axonal damage leading to neuronal loss (*secondary cortical pathology*), or when gray matter (GM) is a direct target of the disease process (*primary cortical pathology*) leading to axonal damage and subsequent demyelination. Findings in post-mortem MS brains support the notion that cortical lesions and cortical subpial demyelination are frequent and extensive, especially in patients with chronic MS, and less commonly observed in early and acute MS [1]. MRI data, however, have demonstrated cortical atrophy even in the earliest stages of the disease [2].

It has been recently shown that 7T MRI can detect and characterize in vivo different histological types of cortical MS plaques [3] including the important class of subpial lesions, underestimated by previous imaging data. Here, in a small group of patients with MS, we relate measurements of cortical thickness to different cortical lesion types detected at 7T, and WM lesion load to assess the unique contribution of different aspects of MS pathology to global and focal cortical thinning.

Methods. Fourteen MS patients (nine with relapsing-remitting MS, RRMS; five with secondary progressive MS, SPMS; mean±SD age=38.9±12.9 years; median Expanded Disability Status Scale=3.0, range=1.0-6.5; mean±SD disease duration=10.2±7.7 years) and eight age-matched controls were scanned twice, within an interval of maximum a month, on a human 7T Siemens scanner using an in-house developed 8- or 32-channel phased array coil, and on a 3T Siemens Tim Trio scanner using the Siemens 32-channel coil. The 7T protocol included acquisition of 2D FLASH-T₂* spoiled gradient-echo weighted images (TR/TE=1000/22 ms, 20, 0.33×0.33×1mm³ slices), and T₂ turbo spin-echo, TSE, scans (TR/TE = 6890/78 ms) with the same resolution and orientation as the FLASH-T₂* scans. For each modality two to three slabs were acquired, allowing coverage of the supratentorial brain. During the 3T session we acquired a high- structural 3D scan with a magnetization-prepared rapid acquisition with multiple gradient echoes (MEMPR) sequence resolution (0.9 x 0.9 x 0.9 mm³, T₁=1200 ms, TR=2530 ms, flip angle=7°, TE=1.7+n.1.88 ms where n = 0, ..., 3, FoV=230 mm, bandwidth=651 Hz/px). Cortical lesions were defined as focal cortical hyperintensities on 7T FLASH-T₂* and T₂-TSE scans by two independent experienced observers and classified as type I (leukocortical), type II (intracortical), type III (subpial), and type IV (subpial extending through the whole cortical width but not to subcortical WM). The load of WM lesions (WMLL) was assessed on 7T FLASH-T₂* scans using a semi-automated contouring technique (Alice, Hayden Solutions). Cortical GM was segmented on the 3T MEMPRAGE scans using FreeSurfer (<http://surfer.nmr.mgh.harvard.edu>), according to a multi-step, automated segmentation procedure that calculates the GM/WM border and the GM/CSF border in the 3D image volume. The cortical reconstruction was used for the following purposes: a) measuring cortical thickness (distance between the GM/WM boundary and the pial surface) in individual participants b) spatial normalization for optimal inter-participant averaging and comparison using a spherical averaging procedure. Statistical thickness difference maps between patients and controls were assessed at each vertex using a random effects model across both hemispheres.

Correlations between cortical thickness measures in each subject, cortical lesions, WMLL, demographic and clinical data were calculated using Spearman rank correlation coefficient (SRCC) and corresponding two-tailed significance levels.

Results. Overall, 188 cortical lesions were detected in patients with MS. The majority of them (N=93) were classified as type III/IV lesions, 69 as type I lesions, and 26 as type II lesions. The mean±SD cortical thickness was lower in patients than in controls (mean±SD: 2.50±0.1 vs 2.60±0.07 mm, p<0.04, by unpaired t-test).

In patients, areas of significant cortical thinning were observed in several brain regions including the bilateral middle frontal gyrus, frontal pole, precentral gyrus, pars orbitalis, supramarginal gyrus, inferior and superior parietal cortex, precuneus, entorhinal cortex, and lateral occipital cortex; the superior frontal gyrus, cingulate cortex, and pars opercularis in the left hemisphere; the superior, middle and inferior temporal gyrus, and fusiform gyrus of right hemisphere. We found that, among all MRI, clinical, and demographic characteristics, only the total number of cortical lesions (SRCC=-0.66, p<0.01) and the number of type III/IV lesions together (SRCC=-0.87, p<0.001) inversely correlated with global cortical thickness in patients. There was only a trend towards significance for age, disease duration and WMLL vs cortical thickness. A cortical surface-based analysis showed that in patients with MS frontal areas including the middle, and superior frontal gyrus, the precentral/postcentral gyri, of both hemispheres showed the highest correlation between cortical thinning and the number of type III/IV lesions (Fig. 1).

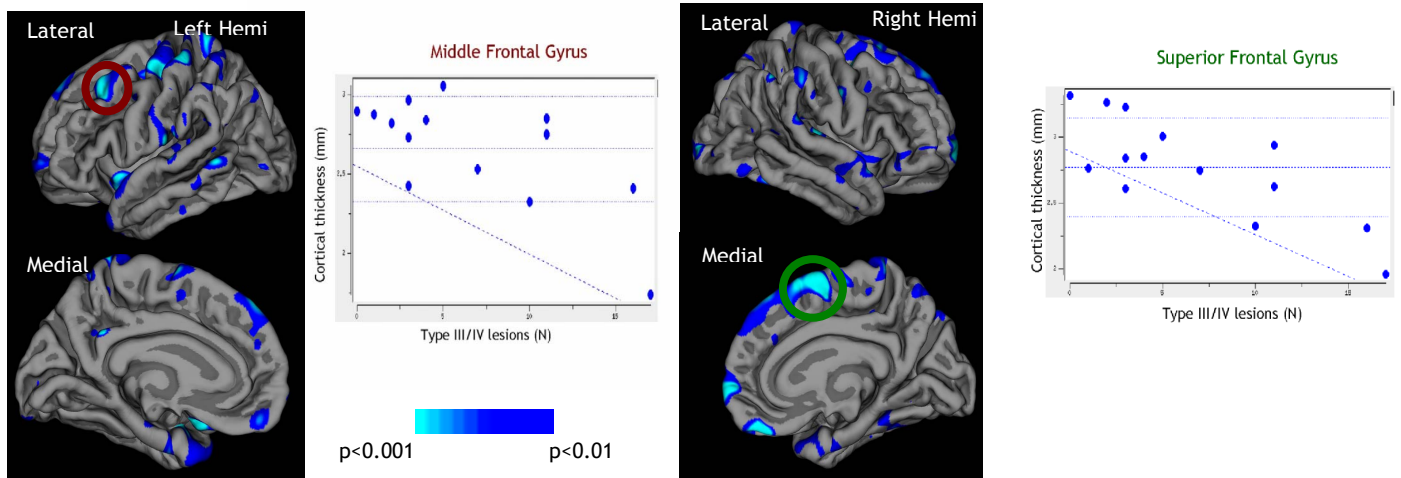


Fig 1. Cortical surface reconstructions showing the effects of type III/IV cortical lesions on cortical thickness in 14 patients with multiple sclerosis. Maps were thresholded at p<0.01. **(left)** In the left hemisphere the higher the number of type III/IV lesions, the thinner several cortical areas were, with the highest effect in the frontal cortex. **(right)** Similar findings were observed in the right hemisphere. The plots on the left and right side of the figure show the relation between the number of type III/IV lesions and individual thickness data in patients for the left middle frontal gyrus and the right superior frontal gyrus respectively.

Conclusions. Our preliminary findings suggest that subpial pathology is a major determinant of cortical atrophy in MS.

References. 1. Stadelmann C. et al., *Curr Opin Neurol* 21:229-34 (2008). 2. Tiberio M. et al, *Neurology* 64:1001-7 (2005). 3. Mainero C., et al. *Neurology* 73:941-8 (2009)

Acknowledgments. This study was partially supported by NIH (5P41 RR14075 08) and NMSS (4281-RG-A-1).