

# Direct Imaging and Quantification of Carotid Plaque Calcification (CPC) Using Ultrashort TE Pulse Sequences

J. Du<sup>1</sup>, J. Corbeil<sup>1</sup>, R. Znamirovski<sup>1</sup>, M. Peterson<sup>2</sup>, N. Angle<sup>3</sup>, G. Bydder<sup>1</sup>, and A. Kahn<sup>4</sup>

<sup>1</sup>Radiology, University of California, San Diego, CA, United States, <sup>2</sup>Pathology, University of California, San Diego, CA, United States, <sup>3</sup>Surgery, University of California, San Diego, CA, United States, <sup>4</sup>Medicine, University of California, San Diego, CA, United States

## INTRODUCTION

Carotid plaque vulnerability is dependent upon its tissue constituents, which may include fibrous tissue, lipid core, intra-plaque hemorrhage and calcified tissue. The degree of plaque calcification has been shown to correlate inversely with symptoms as well as plaque inflammation and vulnerability. Clinical MR sequences, including T1-, T2- and PD-weighted FSE imaging have been employed to characterize the long T2 plaque components (1, 2). However, the short T2 components, including those from calcification, are usually undetectable with conventional clinical MR sequences because of their short transverse relaxation times (3). As a result, carotid calcification appears as a signal void, precluding MR quantification such as measurement of T1, T2\* and water content. Ultrashort TE (UTE) sequences reduce TE down to 100  $\mu$ s or less, and are capable of direct imaging of calcification (4-6). However, use of a short TE alone is usually insufficient to quantitatively visualize calcified tissue, which usually has a much lower proton density than surrounding lipid or fibrous tissue. Efficient suppression of these long T2 tissues is very helpful for high contrast visualization of calcification (4). Here we describe the use of a 2D UTE sequence combined with efficient long T2 suppression to image and characterize carotid plaque calcification using a clinical 3T scanner. High spatial resolution micro-CT images were also acquired for comparison and validation.

## MATERIALS AND METHODS

A 2D UTE sequence with a minimum TE of 8  $\mu$ s was implemented on a clinical GE 3T whole-body scanner. A long adiabatic inversion pulse (8.6 ms in duration) was employed to invert long T2 water and fat magnetization simultaneously. Short T2 signals from calcification were largely uninverted due to the fast transverse relaxation during the long adiabatic inversion process. UTE acquisition starts after a delay time TI which was necessary for the inverted long T2 magnetization to reach the null point. This produced excellent visualization of short T2 calcification (4). T1, T2\* and water content were quantified for each plaque sample. T2\* was quantified using UTE sequences with adiabatic inversion recovery (UTE IR) acquisitions after a series of TE delays. T1 was quantified with a saturation recovery UTE technique where a short hard 90° pulse (232  $\mu$ s) was followed by UTE acquisitions at a series of saturation recovery times (TSR) to detect the recovery of calcification longitudinal magnetization. Water content was quantified by comparing the UTE signal of plaque calcification with a reference phantom, which was a mix of distilled water (20%) and D2O (80%) doped with MnCl<sub>2</sub> to reduce its T2\* to around the T2\* of calcification. Water content was calculated by comparing the corresponding image intensities with correction for T1 and RF attenuation effects (through Bloch equation simulations). In total seven human carotid plaque samples were collected for UTE imaging and evaluation of T1, T2\* and water content using a 1-inch birdcage coil. Typical imaging parameters included a FOV of 5 cm, slice thickness of 0.7 to 1.7 mm, TR of 300 ms, TI of 120 ms, readout of 512, 511 half projections, flip angle of 45°, NEX of 2, bandwidth of  $\pm$ 62.5 kHz, 5 minutes scan time. Clinical T1-, T2- and PD-weighted FSE images were also collected for comparison. Multi-slice CT datasets were acquired with a GE micro-CT system using a high resolution protocol with an isotropic spatial resolution of 90 $\times$ 90 $\times$ 90  $\mu$ m<sup>3</sup> and a total scan time of one hour. The results were qualitatively compared with those from UTE imaging. Mineral density was calculated for each sample. The quantitative UTE MR measurements and mineral density were correlated for the seven carotid plaque specimens.

## RESULTS and DISCUSSION

Figure 1 shows axial imaging of a typical carotid plaque sample using PD-FSE, T1-FSE, GE and UTE IR sequences as well as micro-CT. Clinical FSE or GE sequences show a signal void for calcification. However, this was depicted with high signal and contrast with the UTE IR sequence. For all seven samples there was excellent morphological correlation between UTE IR and micro-CT images. Figure 2 shows T1 and T2\* quantification of the carotid plaque calcification, and demonstrated a short T1 of 94 ms and short T2\* of 376  $\mu$ s. Carotid plaque calcification relaxation times varied significantly from sample to sample, with T1s ranging from 94 $\pm$ 9 to 328 $\pm$ 21 ms, T2\*s ranging from 0.31 $\pm$ 0.12 to 2.15 $\pm$ 0.25 ms, and mobile proton density ranging from 5.7 $\pm$ 2.3% to 16.8 $\pm$ 3.4%. There was a significant increase in T1 ( $R = 0.72$ ;  $P < 0.07$ ) and T2\* ( $R = 0.81$ ;  $P < 0.03$ ) with water content, and a significant decrease ( $R = 0.94$ ;  $P < 0.002$ ) in water content with mineral density.

## CONCLUSIONS

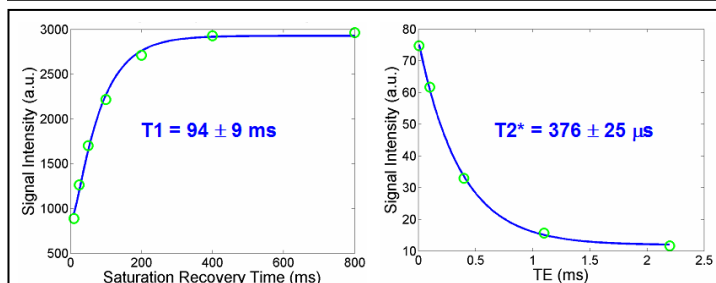
UTE IR enables direct imaging and quantitative characterization of carotid plaque calcification. There was a range of proton density, T1 and T2\* values measured among different samples, which may reflect different levels of hydration and chronicity. This methodology may allow non-invasive MR characterization of plaque calcification, and this may guide risk stratification and treatment of patients with carotid atherosclerosis.

## REFERENCES

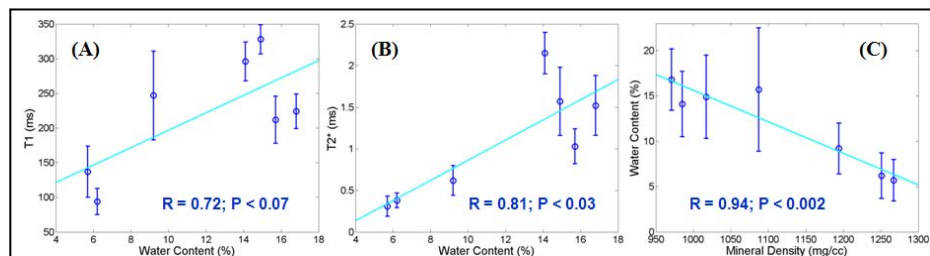
- Hofman et al., MRM 2006 ; 55 :790-799.
- Saam T, et al., Radiology 2007; 244 :64.
- Robson MD, et al., Magn Reson Med 2005; 53:267-274.
- Du J, et al., ISMRM 2007; p381.
- Herzka DA, et al, ISMRM 2008; p962.
- Niellas-Vallespin S, et al., ISMRM 2007; p440.



**Fig 1** Imaging of a carotid sample with fat suppressed PD and T1-FSE, GE, UTE IR and micro-CT. Calcification appears as a signal void in all clinical sequences, and bright with UTE IR and micro-CT (yellow arrows).



**Fig 2** Mono-exponential fitting of the saturation recovery curve (left) and decay curve (right) shows a short T1 of 94 $\pm$ 9 ms and short T2\* of 376 $\pm$ 25  $\mu$ s for calcification of this carotid plaque sample.



**Fig 3** Quantitative analysis of seven carotid specimens shows a significant increase ( $R = 0.72$ ;  $P < 0.07$ ) in T1 with water content (A), a significant increase ( $R = 0.81$ ;  $P < 0.03$ ) in T2\* with water content (B), and a significant decrease ( $R = 0.94$ ;  $P < 0.002$ ) in water content with mineral density (C).