

Nonenhanced Time-resolved MR Angiography for the Arteriovenous Malformation/Fistula of the Pelvis and the Lower Extremity.

M. Akahane¹, J. Sato¹, S. Komatsu¹, Y. Watanabe², Y. Satake², and K. Ohtomo¹

¹Radiology, University of Tokyo, Bunkyo-ku, Tokyo, Japan, ²Clinical Radiology, University of Tokyo, Bunkyo-ku, Tokyo, Japan

Introduction

Nonenhanced magnetic resonance angiography (MRA) using spin-labeling technique in order to distinguish arteries from veins and to suppress the background signals has been applied clinically to renal and hepatic arteries [1,2] for static evaluation of their anatomy and pathological conditions such as stenoses or aneurysms. Spin-labeling MRA can be utilized for the evaluation of hemodynamics as well by altering inversion time (TI) gradually, but TI that is too short or too long will result in increased background signals. In this study, we applied subtraction between spin-labeled and non-labeled MRA to the time-resolved study for better background suppression in any TI.

Material and Methods

Seven patients who underwent nonenhanced MRI for the evaluation of arteriovenous malformations or fistulas of the pelvis or lower extremity in our hospital from May 2007 to November 2009 were included in this study. Mean age was 33.6 years old (range 12-59); three males and four females. Two utero-ovarian lesions were considered to be arteriovenous fistulas; other five lesions were considered to be congenital malformations.

All examination were acquired with 1.5-T scanner (Toshiba EXCELART Vantage, Japan) using the phased-array body coil. Inversion pulse for tagging of arterial blood was placed at just proximal position of the feeding arteries of the lesions. Inversion times (TI) were assigned as 300, 800, 1300 and 1800 ms. Combination of balanced steady state free precession (SSFP) sequences with and without inversion pulse was performed for each TI. Other parameters were as follows: respiratory gated, TR/TE=4.3/2.2 ms, a matrix of 256 × 192, a slice thickness of 5 mm with an interval of 2.5 mm, and an acceleration factor of two using parallel imaging technique. Source images of MRA were prepared by subtraction of images with inversion pulse from images without inversion pulse for each TI, and MRA was obtained by maximum intensity projection (MIP).

Results

Time-resolved MRA was successful in all patients. As TI was increased, high signal in the feeding arteries gradually moved from proximal to distal portion of the lesions. Feeding arteries were selectively depicted in the complex vascular tangles and thus, distinction of feeding arteries and draining veins was easy in all cases. Two of the patients underwent intra-arterial digital subtraction angiography (DSA) after MRA, and images of MRA and DSA were well correlated as shown in Figure 1.

Conclusions

Nonenhanced time-resolved MRA by spin-labeling technique with subtraction is useful for the evaluation of hemodynamics of the arteriovenous malformation or fistula and the distinction of feeding arteries.

Reference

1. Shonai T, et al. J Magn Reson Imaging. 2009 Jun;29(6):1471-7.
2. Shimada K, et al. Eur J Radiol. 2009 Apr;70(1):111-7.

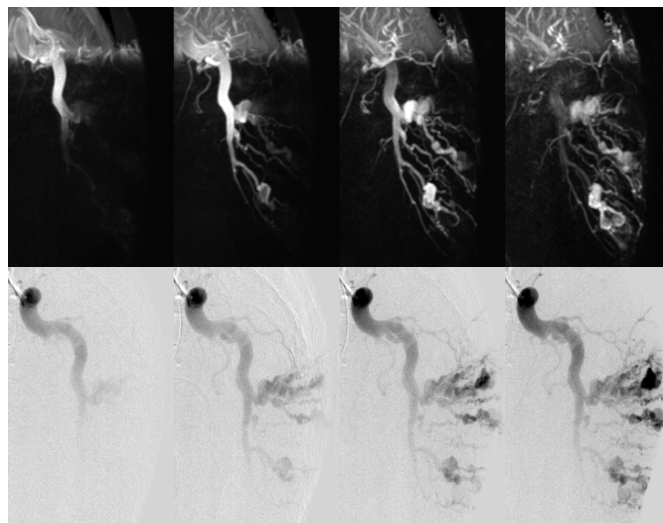


Figure 1. Comparison of nonenhanced time-resolved MRA images on the upper row and corresponding intra-arterial DSA images on the lower row. DSA were obtained with an interval of 500 ms as well as MRA.