

Non contrast MRA of the Renal Artery: Comparison of Respiratory Triggered IFIR and ECG gated IFIR with Autovoice Guidance for Respiration

T. Masui¹, M. Katayama¹, K. Sato¹, H. Ikuma¹, M. Sugimura¹, M. Ishii¹, N. Takei², and M. Miyoshi²

¹Radiology, Seirei Hamamatsu General Hospital, Hamamatsu, Japan, ²Japan Applied Science Laboratory, GE Healthcare Japan, Hino, Japan

Introduction; For evaluation of patients with renal insufficiency or history with adverse reactions, MR contrast media cannot be used. Non-contrast (NC) MRAs with several techniques have been introduced. An investigational version of Inherent Enhancement (Inhance) Inflow IR: InFlow Inversion Recovery (IFIR) technique with FIESTA has been evaluated and respiratory triggered IFIR with FIESTA can demonstrate peripheral part of the renal arteries (1). However, focusing on the peripheral renal arteries, respiratory triggered IFIR without ECG gating showed some irregularity in the distal part of the renal arteries. As in the case for demonstration of the coronary arteries, respiratory triggered or navigating in combined use with ECG gating technique may solve the problem. And another approach might be to facilitate the regular respiratory cycle with ECG gating. And in the current study, we tried to maintain the regular respiratory cycle with autovoice for guidance of respiration. Accordingly, the purpose was to evaluate effect of autovoice guidance for respiratory cycle with ECG gating on the quality of NC MRA using IFIR for the demonstration of renal arteries in comparison with contrast MRA.

Materials and Methods: Population: 23 patients (17 men, 6 women, mean age 62 years) were included, who underwent contrast enhanced MR imaging for evaluation of renal tumor and renal arteries. Pathologies were renal cancer in 3, pelvic tumor in 1, renal benign lesions in 5, miscellaneous in 10, and normal in 4. **MR imaging:** All images were obtained on a 1.5T MR (HDxt, GE, Milwaukee) with 8 channel phased array multicoils. 1) NC-MRA using an investigational version of Inflow IR, IFIR (Fig 1) with autovoice guidance for respiration 12 times per minute (Fig 1), ECG gated 3D FIESTA was obtained in the axial plane with 3.8ms/1.9ms/90deg/35cm/2mm/256x224-256/ZIP2 110-180 slices/ 0.75NEX with Spec IR and inversion time of 1300ms/RF 2 (ECG IFIR with autovoice) 2) NC MRA with the same parameters except with only respiratory triggering without ECG gating (IFIR with resp trigger)(Fig 2). 3) C MRA was obtained with 3D gradient echo sequence (EFGRE) using 2.9ms/0.9ms/20 deg/35cm/2mm/256x192 /one NEX/Spec IR/RF2, centric k space ordering. 0.1mmol/kg of gadolinium was injected (0.3ml/sec) and five seconds after arrival of contrast with smart prep (GEHC), breath-hold 3D EFGRE was obtained in 24 seconds. **Data analysis:** Image quality, artifacts (blurring), and overlap of the renal artery and veins were ranked with 5 -point scale (form 1 undiagnostic, bad to 5 excellent, no artifacts). Recognitions of aorta at upper (from diaphragm) and lower (to bifurcation) levels, renal arteries at five levels (proximal, middle, distal, 2nd, and 3rd order) were ranked with 5-point scale (1 bad to 5 good). Subjective evaluations were performed by two radiologists. Wilcoxon signed rank test was used for comparison among three MRA using Bonferoni Correction (P<0.0167). All evaluations were made on workstation (Advantage workstation 4.4, GE) by two radiologists and MIP images were generated from each data using MPVR by readers.

Results: In 23 patients, all MRAs were diagnostic except one case with C MRA. Overall image quality was not significantly different among three MRAs but regarding artifacts and overlap of the structures, ECG IFIR with autovoice was better (NS, Fig 3-5). Peripheral renal arteries were also better visualized on ECG IFIR with autovoice than on other MRAs (NS, Fig 4, 5). However, in four cases, image quality was better on IFIR with resp trigger than on ECG IFIR with autovoice due to irregular respiration against the autovoice guidance.

Summary: NC MRA better visualized renal arteries without overlaps of the structures. NC MRA with IFIR visualized peripheral renal arteries in detail. And ECG gated IFIR with autovoice guidance can provide best image quality of the peripheral renal arteries when autovoice successfully trigger respiration. C MRA might miss the optimal timing for selective visualization of the renal arteries without overlaps of the structures. In conclusion, for evaluation of renal arteries especially in the peripheral portions, use of ECG gated NC MRA with autovoice guiding the regular respiration can provide excellent information, which might be better than that obtained with C MRA.

[1]Masui T. et al., the proceeding of ISMRM (2009)

Fig 1. IFIR with Auto-voice

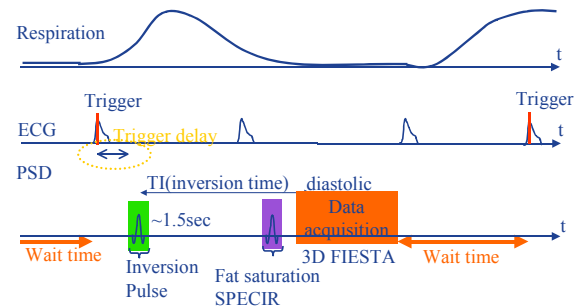
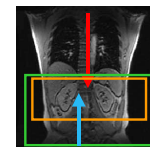
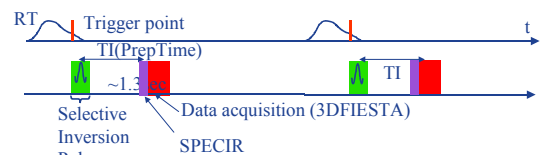


Fig 2. IFIR with Resp. Trigger



Orange: Imaging, Green: Selective inversion pulse
Red: Artery, Blue: Vein

Fig 3. Quality, Artifact *p<0.0167 Auto vs Resp
#p<0.0167 Auto vs C MRA

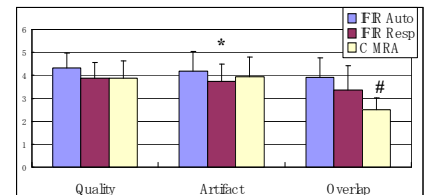


Fig 4. Visualization of Renal Arteries

*p<0.0167 Auto vs Resp
#p<0.0167 Auto vs C MRA

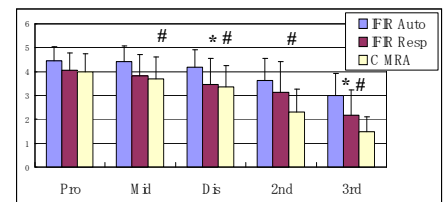


Fig5c C MRA

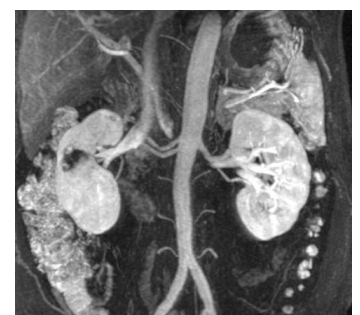

Fig 5a ECG gated IFIR with autovoice

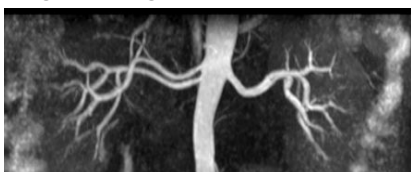


Fig 5b IFIR with resp trigger

