

Preferential patterns of myocardial iron deposition by multislice multiecho T2* CMR in thalassemia major patients.

A. Meloni¹, V. Positano¹, A. Pepe¹, P. Pepe¹, M. C. Dell'Amico¹, C. Salvatori¹, P. Keilberg¹, G. Valeri², E. Cracolici³, P. Bitti⁴, A. Zuccarelli⁵, M. F. Santarelli¹, and M. Lombardi¹

¹MRI Lab, "G. Monasterio Foundation" and Institute of Clinical Physiology, CNR, Pisa, Italy, ²Azienda Ospedaliero-Universitaria Ospedali Riuniti "Umberto I-Lancisi-Salesi", Ancona, Italy, ³Policlinico "Paolo Giaccone", Palermo, Italy, ⁴Dipartimento dei Servizi - P. O. San Francesco, Nuoro, Italy, ⁵Centro trasfusionale e di microcitemia - Ospedale civile, Olbia, Italy

Introduction: T2* multislice multiecho cardiac magnetic resonance (CMR) technique has permitted quantification of myocardial iron overload (MIO) by a segmental approach [1]. Little is known in the literature about patterns of iron store in hemochromatosis. Our study aimed to investigate myocardial iron overload in thalassemia major (TM) patients by segmental T2* CMR technique, in order to determine if there were preferential patterns of iron deposit.

Materials and methods: Five hundred and nineteen TM patients underwent CMR. Three parallel short-axis views (basal, medium, and apical) of the left ventricle were obtained by a T2* gradient-echo multiecho sequence. The images were analyzed using a previously validated, custom-written software (HIPPO-MIOT IFC-CNR[®]) [2]. The myocardium was automatically segmented into a 16-segment standardized LV model [3] and the T2* value on each segment was calculated. The global T2* value averaged over all 16 segmental T2* values, as well as the mean values over the basal, middle, and apical slices were automatically provided. The T2* value in the mid-ventricular septum was evaluated by averaging the T2* values in segments 8 and 9. Four different main circumferential regions were defined by averaging the corresponding segmental T2* values: anterior (segments 1,7,13), septal (segments 2,3,8,9,14), inferior (segments 4,10,15) and lateral (segments 5,6,11,12,16).

Results: Two-hundred and twenty-nine patients showed global T2* value < 26 ms, corresponding to significant global heart iron overload [4]. The analysis was focused on this patient population, subsequently divided into two groups: severe iron overload (N = 83, global T2* < 10 ms) and mild-moderate iron overload (N = 146, global T2* between 10 and 26 ms). For each group, segments were sorted by mean T2* value. Segment order was significantly preserved between the two groups (r = 0.91, P < 0.0001). Significant circumferential variability was found in patients with overall heart iron overload (figure 1A) as well as in both groups (P < 0.0001). The mean T2* value over the anterior region was significantly lower than the mean T2* values over the other regions and the mean T2* over the inferior region was significantly lower than the T2* values over the septal and lateral regions (figure 1B). This pattern was preserved within each single slice (figure 1C). We found a significantly higher T2* value in the basal slice versus the medium and apical slices in patients with severe iron overload.

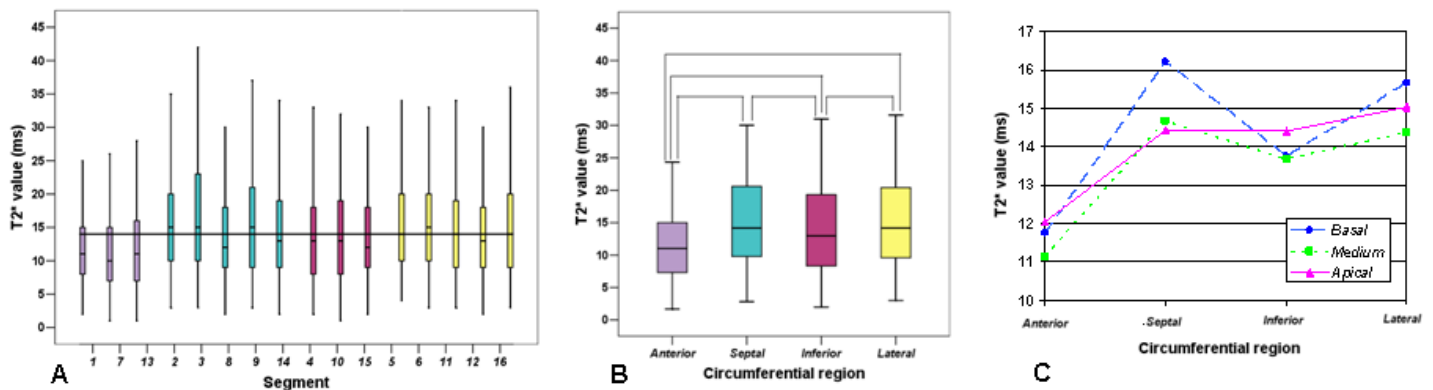


Figure 1: CMR results in the patients with the global heart T2* value < 26 ms. Segmental T2* variability (A). Circumferential T2* variability (B). Mean circumferential T2* values in each slice (C).

Discussion and Conclusions: A preferential pattern of iron store in anterior and inferior regions appears to be present in TM patients with severe and mild-moderate iron overload. The preserved pattern between the groups prevents attributing this datum to additive susceptibility artefacts, which are negligible in heavily iron-loaded patients. A segmental T2* CMR approach could identify early iron deposit, useful for tailoring chelation therapy and preventing myocardial dysfunction in the clinical setting.

References: [1] Pepe A et al. JMRI 2006;23(5):662-668. [2] Positano V et al. NMR Biomed 2007;20(6):578-90. [3] Cerqueira MD et al. Circulation 2002 ;105:539-542. [4] Ramazzotti A et al. JMRI 2009;30:62-68.