

Estimation of LV function from navigator triggered, real-time cardiac cine steady-state free precession (SSFP) imaging

A. Pednekar¹, B. Cheong², R. Muthupillai², and C. Arena²

¹Philips Healthcare, Cleveland, OH, United States, ²Diagnostic and Interventional Radiology, St. Luke's Episcopal Hospital, Houston, TX, United States

Introduction: Despite recent advances in fast cardiac cine imaging with techniques such SENSE and k-t BLAST, in some specific patient populations with sustained arrhythmias it is difficult to obtain gated cardiac cine SSFP images using the segmented k-space acquisitions. We hypothesize that a real-time cine MR technique that can acquire cardiac cine images over three to four cardiac cycles can be analyzed using a semi-automated LV segmentation algorithm to retrospectively analyze and evaluate cardiac function. The purpose of this work is to test the validity of this hypothesis.

Materials and Methods:

Subjects: Eight subjects in normal sinus rhythm (6 male, 36 ± 6 yrs were imaged on a 1.5T Achieva (Philips healthcare) using a 32 channel cardiac coil for signal reception and VCG gating. All subjects provided written informed consent.

MRI Acquisition: Real-time cine SSFP images in the short-axis orientation covering the entire left ventricle (LV) were acquired with the following parameters: TR/TE/flip angle: 2.2/1.1/55°; acquired voxel size: 3 x 3 x 8 mm³; Sensitivity Encoding (SENSE) acceleration factor: 3; temporal resolution: 72-86 ms; After a single cardiac trigger, unsegmented cine images were acquired for 3-4 seconds capturing 3-4 heartbeats, before proceeding to acquire the next slice. Navigator triggering was used to ensure consistency of diaphragmatic position between slices. For purposes of comparison, conventional, segmented cine SSFP images with a voxel size of: 2x2x8 mm³; temporal resolution: 30-40 ms; imaging time : 4-5 RR intervals/slice were also acquired.

LV Segmentation: The algorithm involves: 1) automatically recognize LV; 2) classify partial volumed pixels as blood or muscle using periodic intensity variation intrinsic to the cardiac cine-MR; and 3) incorporate smoothness of the LV shape through convex, closed, and piecewise parametric curve to delineate endocardial boundary (see Figure 1, details in [1,2]).

Inline Processing: The EF computation program automatically runs in the background as a part of the acquisition protocol on the console of a 1.5T Philips Achieva clinical scanner (Intel Xeon, 3.20GHz, 6GB RAM). The program seamlessly retrieves, processes, and saves resultant delineated LV images back into the patient database, with ED and ES contours.

Data Analysis: An experienced observer drew the contours on the conventional segmented k-space cine SSFP images to estimate the LV end-diastolic and systolic volumes. The automated algorithm was used to estimate slice-by-slice volume across all cardiac phases.

Real-time cine MR slices were analyzed using our algorithm (A) and manually by a clinical expert (R). The only user input to the processing algorithm was to specify the basal and apical slice numbers.

Results: The processing time was 80-120 ms/slice. Processing of real-time images captured at least two to three cardiac cycles for each slice. The LV volumes for each cardiac phase per slice was calculated and sorted and binned to result in the lowest LV volume (end-systolic volume), and the largest LV volume (end-diastolic volume) for that slice. A comparison of the LV volumes estimated from the real-time imaging technique and automated in-line processing, and conventional cine SSFP images is shown in Figure 2 and 3. [1].

Conclusions: The results from the study suggest that it is feasible to obtain of LV volumes using real-time, unsegmented cine MR imaging and dedicated retrospective image analysis methods that are comparable to LV volumes obtained using conventional, cardiac gated segmented cine MR techniques.

References: 1. J. Magn. Reson. Imaging 2008; 28:39–50. 2. ISMRM 09; 3749.

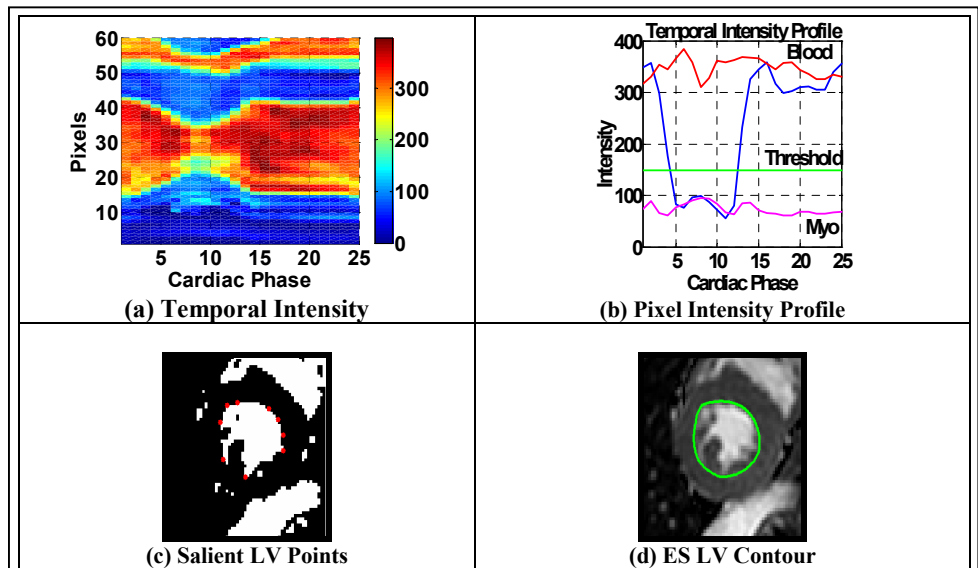


Figure 1: Graphical outline of LV segmentation process. For details of each step, please see text.

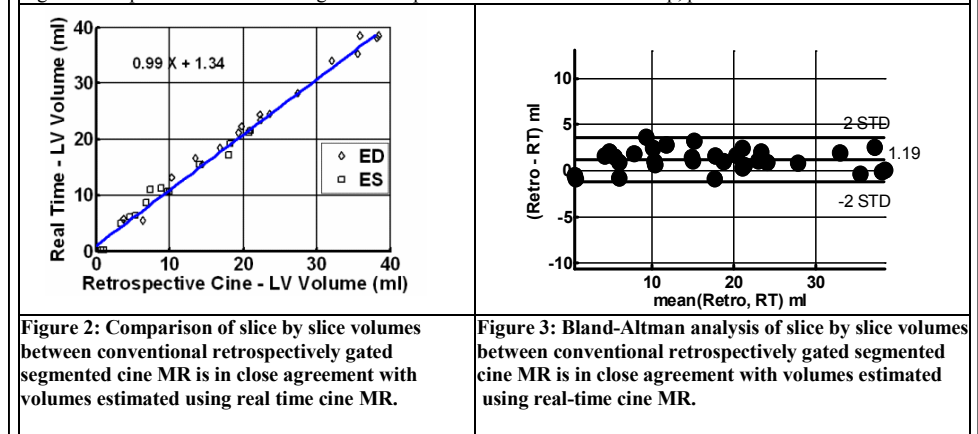


Figure 2: Comparison of slice by slice volumes between conventional retrospectively gated segmented cine MR is in close agreement with volumes estimated using real time cine MR.

Figure 3: Bland-Altman analysis of slice by slice volumes between conventional retrospectively gated segmented cine MR is in close agreement with volumes estimated using real-time cine MR.