

## Elevated Aortic Wall Shear Stress in a Subgroup of Patients with Bicuspid Valves

M. D. Hope<sup>1</sup>, T. A. Hope<sup>1</sup>, T. H. Urbania<sup>1</sup>, K. G. Ordovas<sup>1</sup>, A. K. Meadows<sup>1</sup>, M. T. Alley<sup>2</sup>, and C. B. Higgins<sup>1</sup>  
<sup>1</sup>Radiology, UCSF, San Francisco, CA, United States, <sup>2</sup>Stanford Radiology

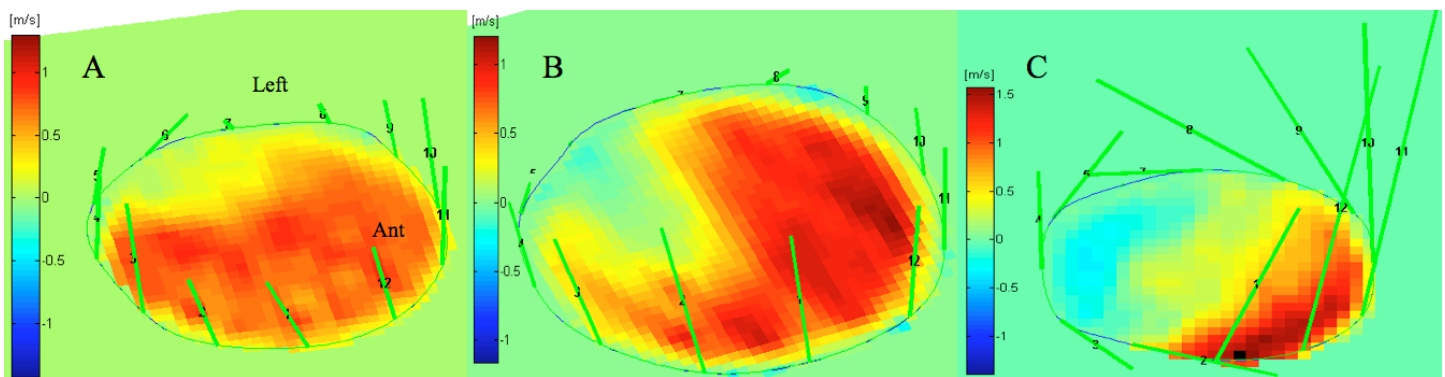
**Introduction:** The role altered hemodynamics play in dilation of the ascending thoracic aorta (AsAo) in bicuspid aortic valve (BAV) patients is controversial [1]. We previously reported that abnormal systolic helical flow is a common finding in the AsAo of BAV, but not tricuspid aortic valve (TAV), patients [2]. We now seek to further characterize the altered fluid-mechanical environment in the AsAo of these patients with the goal uncovering a subset of patients that may be at increased risk of developing aneurysm.

**Subjects and Methods:** Time-resolved, 3D phase contrast MRI (4D Flow) [3] was used to assess AsAo blood flow in 55 individuals: 26 patients with BAV and 21 with TAV, and 8 healthy volunteers. Scans were performed with VENCs of 160-200 cm/s, spatial resolution of 1.17 x 1.56 x 2.6 mm<sup>3</sup>, and temporal resolution of 74-77 ms. Systolic flow patterns were characterized with 3D visualization software (EnSight, CEI, Inc. Apex NC). Abnormal helical flow was defined as greater than 180° curvature of the majority of high velocity peak systolic streamlines around slower, central helical flow in the AsAo. Vectorial wall shear stress (vWSS) was calculated at peak systole for 12 angular segments along the AsAo circumference just above the level of the sinotubular junction using proprietary software (*flow tool*, University of Freiburg) [4].

**Results:** Abnormal helical flow was demonstrated at peak systole in the AsAo of 20 of 26 BAV patients, but in none of the TAV patients or healthy volunteers. Right-handed helical flow was seen in patients with RL aortic leaflet fusion, whereas left-handed helical flow was seen with RN leaflet fusion. **Figures 1** demonstrates shear stress analysis at peak systole for a healthy volunteer, a BAV patient with normal flow, and a BAV patient with right-handed helical flow. Peak systolic vWSS was elevated in the right-anterior quadrant of the AsAo in BAV patients with right-handed helical flow (n = 16) compared to TAV controls: 1.36 versus 0.52 N/m<sup>2</sup>, p < 0.001. No significant difference was found between BAV patients with normal flow (n = 6) and TAV controls. Analysis of BAV patients with left-handed helical flow (n = 4) was limited by signal aliasing related to aortic stenosis.

**Discussion:** 4D Flow demonstrates significantly higher aortic wall shear stress in a subgroup of BAV patients with eccentric systolic flow jets. Studies have shown that only a subset of BAV patients have aortic dilation [5], and that those with dilation develop asymmetric aneurysms of the AsAo at the location where we have demonstrated elevated vWSS [6]. As altered WSS can give rise to pathologic endothelial gene expression and extracellular matrix remodeling [7], we may have identified the mechanism that places a subgroup of BAV patients at risk for asymmetric AsAo aneurysm.

**References:** [1] Guntheroth WG et al. Am J Cardiol 2008;102:107-110. [2] Hope MD et al. ISMRM abstract 2009. [3] Markl M et al. J Magn Reson Imaging 2003;17:499-506. [4] Stalder AF et al. Magn Reson Med 2008;60:1218-1231. [5] Nistri S et al. Heart 1999;82:19-22. [6] Bauer M et al. J Heart Valve Dis 2006;15(5):594-600. [7] Malek AM et al. JAMA 1999;282(21):2035-42.



**Figure 1:** Systolic wall shear stress analysis at the level of the sinotubular junction. Color-coded velocity has been mapped onto the 2D plane. **A** demonstrates a central velocity profile and normal distribution of shear stress in a healthy volunteer. The plane orientation labeled applies to all three images. **B** shows a similar velocity and shear stress profile in a patient with BAV and normal systolic flow. **C** illustrates skewing of systolic flow with a right anterior flow jet in a BAV patient with RL leaflet fusion and right-handed helical systolic flow. Note the elevated shear stress along the right-anterior AsAo wall.