

Approaching Complete Separation of Benign and Malignant Breast Lesions by DCE-MRI: Impact on Healthcare Costs

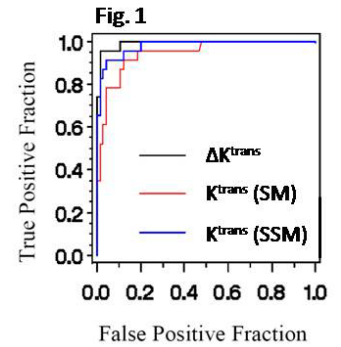
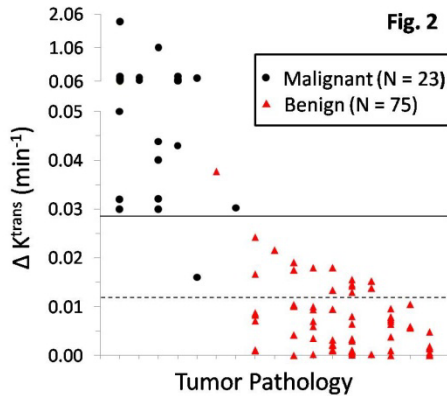
W. Huang¹, P. A. Carney¹, L. A. Tudorica¹, Y. Chen¹, X. Li¹, E. A. Morris², I. J. Tagge¹, S. Thakur², M. Korenblit², J. A. Koutcher², and C. S. Springer¹
¹Oregon Health & Science University, Portland, OR, United States, ²Memorial Sloan Kettering Cancer Center, New York, NY, United States

INTRODUCTION Though having excellent sensitivity for breast cancer detection, as currently implemented in clinical practice, MRI suffers limited diagnostic specificity. This results in large numbers of biopsies yielding benign pathologies, which are unnecessary in this sense. Dynamic contrast-enhanced (DCE) MRI is an important part of a breast MRI exam. Qualitative or semi-quantitative analyses of DCE-MRI time-course data are often used in clinical diagnoses. However, the results are often dependent on data acquisition details, contrast agent (CA) dose and/or injection rate, etc. This contributes to the limited specificity and study irreproducibility of clinical breast MRI protocols (1). Quantitative analysis of DCE-MRI time-course using a pharmacokinetic model to extract pharmacokinetic parameters (such as K^{trans} and v_e) is more desirable, as these parameters are physiological quantities, in principle independent of the above factors. It has been shown, in a cohort of 22 suspicious breast lesions (2,3), that the Shutter-Speed Model (SSM, accounting for finite transcytolemmal water exchange kinetics) DCE-MRI method (4) significantly improves breast cancer diagnostic accuracy compared to Standard Model (SM, assuming these kinetics to be effectively infinitely fast) DCE-MRI (5) and clinical MRI protocols. Further, the newly discovered DCE-MRI biomarker, $\Delta K^{trans} \equiv K^{trans}(\text{SSM}) - K^{trans}(\text{SM})$, achieved perfect sensitivity and specificity in this small population. ΔK^{trans} is a measure of K^{trans} underestimation due to the SM's neglect of the finite water exchange kinetics (a shutter-speed effect) (2,3). The current study of a population over 4X larger further validates the SSM DCE-MRI diagnostic accuracy for breast cancer, and evaluates the cost effectiveness if SSM DCE-MRI were to replace unnecessary benign biopsy procedures.

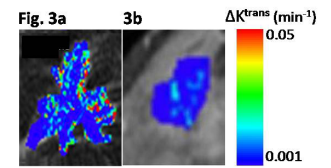
METHODS A total of 95 patients underwent clinical breast MRI protocols and had 98 contrast-enhanced lesions (3 patients presented 2 lesions each) radiologically classified in the BIRADS (Breast Imaging Reporting and Data System) 4 (B-4, suspicious, n = 87) or 5 (B-5, highly suggestive of malignancy, n = 11) categories, leading to biopsy referrals. The research DCE-MRI data acquisitions were IRB-approved and performed prior to biopsy procedures.

The study was conducted at 1.5T using a body transmit and a four- or seven-channel phased-array bilateral breast receive RF coils. A 3D SPGR pulse sequence was used to acquire 12-20 serial sagittal image volume sets continually, spatially covering the whole breast with the suspicious lesion(s) to be biopsied. Other parameters included 10° or 30° (for 6 lesions only) flip angle, 2-5 ms TE, 6-9 ms TR, 3 mm section thickness, 20-24 cm FOV. Depending on the breast size, 16-40 image slices were acquired for each set, resulting in inter-sampling interval (temporal resolution) of 13-44 s. At the start of the second volume set acquisition, Gd CA was delivered intravenously [0.1 mmol/kg at 2 mL/s]. ROIs circumscribing the enhanced lesion and within an axillary artery produced the tumor signal intensity and arterial input function (AIF) time-courses, respectively. Three reliable individual AIFs were measured, interpolated with an empirical expression (4), and averaged to generate a mean AIF. The tumor ROI and mean AIF signal time-courses were then subjected to both SM and SSM analyses (2,3), which were blinded from the pathology. Receiver-operating-characteristic (ROC) curves were used to evaluate pharmacokinetic parameter diagnostic accuracies, and the areas under the curve (AUCs) were compared using a Bootstrap nonparametric test. National Cancer Institute Breast Cancer Surveillance Consortium (BCSC) findings and the National Medicare reimbursement allowance rates were used to estimate the cost effectiveness of SSM DCE-MRI replacing unnecessary benign biopsies.

RESULTS Upon pathology, only 23 lesions (14 B-4 and 9 B-5) were found malignant and the other 75 (73 B-4 and 2 B-5) benign. The positive predictive value (PPV) of the clinical MRI protocol is only 23%. Fig. 1 shows the ROC plots for lesion ROI-averaged $K^{trans}(\text{SM})$, $K^{trans}(\text{SSM})$, and ΔK^{trans} values, each as a diagnostic marker. The $K^{trans}(\text{SSM})$ ROC AUC is significantly greater than the $K^{trans}(\text{SM})$ AUC (0.98 vs. 0.95, p = 0.02). The ΔK^{trans} AUC is even greater than the $K^{trans}(\text{SSM})$ AUC (0.99 vs. 0.98) [though not statistically significant (p = 0.24)], indicating that the ΔK^{trans} biomarker has the greatest diagnostic accuracy with 89% specificity at 100% sensitivity for this study population. An explicit view of this is provided in Fig. 2, the scatter plot of all lesion ROI ΔK^{trans} values.



Each column represents one pathology category, and these are ranked roughly in order of decreasing mean ΔK^{trans} from left to right (6). The malignant lesions (black circles) cluster almost exclusively on the left of Fig. 2, while the benign lesions (red triangles) are almost all to the right. Note the ordinate scale break. The solid cut-off line, at 0.028 min^{-1} , that results in complete separation of benign and malignant lesions for the first 22 patients studied (2,3), remarkably produces only one false positive (the sole tubular adenoma) and only one false negative [one of the two pure invasive lobular carcinomas (ILC)] in this more than quadrupled population. To eliminate the partial-volume averaging effects of ROI analysis, pixel-by-pixel pharmacokinetic mapping can be performed on the same data. This is useful for cases with ROI ΔK^{trans} values falling between the solid and dashed (0.012 min^{-1}) Fig. 2 cut-off lines. [The latter was drawn to ensure 100% sensitivity, thus suffering more false positives] Fig. 3 shows a pair of



color ΔK^{trans} maps from a malignant ILC tumor (Fig. 3a, false negative based on the solid cut-off line) and a benign lesion with atypical ductal hyperplasia (ADH) (Fig. 3b), overlaid on DCE images. Though the ROI ΔK^{trans} value of each lesion is between the two cut-off lines, there are hot spots ($\Delta K^{trans} > 0.05 \text{ min}^{-1}$) in the ILC posterior rim region, while none in the ADH, or other benign lesions between the cut-off lines. Thus, the combination of ROI ΔK^{trans} analysis and pixel-by-pixel mapping improves specificity further to 99% [74/(74 + 1)]. The AUCs of the $v_e(\text{SM})$ and $v_e(\text{SSM})$ ROC plots (not shown) are 0.555 and 0.585, respectively, suggesting that v_e is a poor diagnostic marker.

If SSM DCE-MRI were to replace all unnecessary benign biopsies following positive mammography and/or sonography screening and diagnosis, a cost analysis reveals an additional cost of only 11.4 k\$ per 100,000 women screened for breast cancer, or 11 ¢ per individual. This is essentially cost neutral. Over 200,000 biopsy procedures on benign breasts could be avoided annually in the U.S. If one considers the cost of biopsy morbidity, there would be considerable savings.

DISCUSSION It is apparent that the shutter-speed (exchange) effect is significant for only the malignant breast tumors ($\Delta K^{trans} = 0$ means no effect). The results of this study show that SSM DCE-MRI significantly improves breast cancer diagnostic accuracy compared to SM DCE-MRI and clinical MRI protocols. Since mammography and sonography are each so much less expensive than MRI, they will surely remain integral in initial screening and diagnosis. However, use of SSM DCE-MRI following positive mammography and/or sonography screening and diagnosis not only reduces/avoids unnecessary benign biopsies, but also is cost effective. A "benign" pharmacokinetic parameter probably should not prevent a morphologically suspicious (such as spiculated) lesion from biopsy. Thus, SSM DCE-MRI will most likely benefit patients with B-4 lesions, which are suspicious but have no compelling features. The B-4 lesions constitute the majority of those referred for biopsies: 89% in this study population.

REFERENCES 1. Jansen SA, et al. *AJR* 2009;193:832-839. 2. Huang W, et al. *Proc Natl Acad Sci* 2008; 105:17943-17948. 3. Li X, et al. *Proc Natl Acad Sci* 2008; 105:17937-17942. 4. Yankeelov TE, et al. *Magn Reson Med* 2003; 50:1151-1169. 5. Tofts PS, et al. *JMRI* 1999; 10:223-232. 6. Huang W, et al. *Proc Int Soc Magn Reson Med* 2009;17:4240.