

WHOLE HEART T1 WEIGHTED CORONARY PLAQUE MR IMAGING AT 3T USING 32CHANNEL CARDIAC COILS

H. Miyagi¹, H. Sakuma¹, S. Kato¹, K. Kitagawa¹, M. Nagata¹, T. Shinichi¹, S. Andreas¹, M. Miyahara², M. Nakamura², Y. Mitani³, and H. Ohashi³

¹Department of Radiology, Mie University Hospital, Tsu, Mie, Japan, ²Department of Cardiology, Mie University Hospital, Tsu, Mie, Japan, ³Department of Pediatrics, Mie University Hospital, Tsu, Mie, Japan

Background: In previous studies using T1 weighted MR imaging for carotid plaque characterization, hyperintense atherosclerotic plaques correlated with complicated plaques with lipid-rich core and/or intraplaque hemorrhage. A recent study using 1.5T MR imager demonstrated that non-contrast enhanced T1-weighted gradient echo MR imaging may be useful for the assessment of coronary plaque characterization in patients with coronary artery disease (CAD). However, because of the small size of the coronary artery and the need for ECG triggering and respiratory gating, improved signal-to-noise ratio is required for reliable assessment of coronary plaque. The aim of this study was to evaluate the feasibility of coronary plaque imaging using a 3T MR imager and 32-channel cardiac coils. Three dimensional, T1 weighted turbo spin echo (TSE) images covering the entire heart were acquired in patients with Kawasaki disease and patients with CAD.

Materials and Methods: Ten patients with Kawasaki disease who had coronary artery aneurysms (averaged age: 20.4 ± 4.7 year) and 5 patients with significant CAD (averaged age: 66.2 ± 9.5 year) were studied by using a 3T MR imager (Achieva) and 32 channel cardiac coils. Three-dimensional, saturation recovery prepared TSE MR images covering the entire heart were obtained on axial imaging planes with TR /TE /FA of 1R-R /39msec /90 degree, refocusing control angle of 30 degree, TSE factor of 10, delay time between saturation pre-pulse and image acquisition of 400 msec, SPIR fat suppression, SENSE factor of 4, field of view of 320 x 256 x 127mm, acquisition matrix of 192 x 154 x 65 and reconstruction voxel size of 0.63 x 0.63 x 0.9mm. Two observers determined the images quality score of whole heart coronary plaque MR images (4: excellent, 3: good, 2: fair, 1: poor) and evaluated the presence or absence of hyperintense coronary plaque (HIP). Multidetector-row computed tomography (MDCT) was performed in all patients with Kawasaki disease.

Results: Whole-heart T1 weighted coronary plaque MR images were successfully acquired in all subjects (Figure 1). The averaged imaging time was 7.9 ± 1.6 min in patients with Kawasaki disease and 8.0 ± 2.0 min in patients with CAD. The mean image quality score was 3.9 ± 0.3 in the right coronary artery (RCA), 3.7 ± 0.6 in the left anterior descending artery and 3.6 ± 0.6 in the circumflex artery, respectively. In patients with Kawasaki disease, HIP was observed in 5 of 30 major coronary arteries and in 5 of 10 patients. When compared with MDCT images, these HIP lesions were observed in the thrombus within coronary artery aneurysms. In CAD patients, HIP was found in 4 of 15 major coronary arteries in 4 of 5 patients. Intravascular ultrasound (IVUS) revealed that HIP corresponded to thrombus along the vessel wall or positive remodeling plaque with ultrasound attenuation.

Conclusions: The current results in patients with Kawasaki disease and patients with CAD indicate that whole-heart T1 weighted coronary plaque MR imaging at 3T is feasible by employing WET saturation pulse and free-breathing 3D TSE acquisition. With use of 32 channel cardiac coils and high SENSE factor, the presence of HIP in the entire coronary artery tree can be screened with an averaged imaging time of less than 10 minutes.

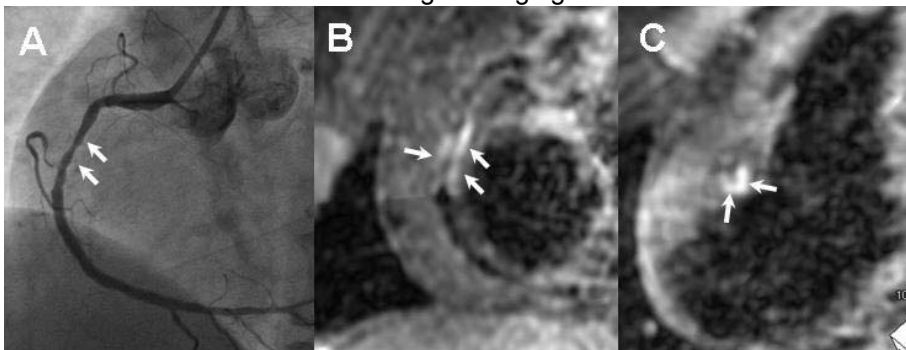


Figure 1. X-ray coronary angiogram and T1 weighted whole heart coronary plaque MRI in a patient with CAD. X-ray angiogram (A) revealed significant stenosis in RCA (arrows). Hyperintense coronary plaque was clearly revealed on sliding thin SLAB MIP images reconstructed along RCA (B) and perpendicular to RCA (C).