

Imaging of inflammation using VSOP and T2* mapping in a mouse model of myocardial infarction

A. Protti¹, A. Sirker¹, X. Dong¹, M. Andia², A. M. Shah¹, and R. Botnar²

¹Cardiovascular Division, King's College London BHF Centre of Excellence, London, United Kingdom, ²Division of Imaging Sciences, King's College London BHF Centre of Excellence, London, United Kingdom

Introduction

Inflammation is thought to play an important role in cardiac repair after myocardial infarction. Resolution and containment of inflammation is believed to be essential for optimal infarct healing. The development of non-invasive imaging methods is therefore of great interest for the in-vivo investigation of the inflammatory response post MI and has been demonstrated recently (1). MRI of post MI inflammation was performed with a dextran coated iron oxide nanoparticle, which have been shown to be phagocytosed by macrophages and to generate dark spots due to their T2* enhancing properties (2). In this work, we sought to investigate the merits of a very small superparamagnetic iron oxide particle (VSOP) (3) for direct imaging of inflammation in a mouse model of MI and to quantify T2* using multi echo gradient echo images.

Method

Three C57Bl6 mice were subjected to occlusion reperfusion injury of the myocardium to generate an inflammatory response in the myocardium. 15 μ l of VSOP (250 μ mol/kg, 15mg iron/kg) were injected intravenously 1 day after surgery and MRI was performed 48 hours after VSOP injection. After sedation of the animal with an isoflurane-oxygen mixture, images were acquired on a 7T horizontal-bore MR scanner (Varian, USA), with a gradient strength of 1000mT/m and a 39mm RF coil (Rapid, Germany). A T2* weighted gradient echo (FLASH) sequence was used to detect VSOP uptake in the infarct area. Imaging parameters included TR=heart rate; TE = 0.68, 1, 3 and 5 ms; matrix = 128x128; FOV = 25x25mm; 1mm slice thickness; 7 slices; 3 averages and acquisition time = 8 minutes. For assessment of functional and volumetric information, a cine-FLASH sequence was used. Relevant imaging parameters included TR=heart rate; TE = 1ms; matrix = 128x128; FOV = 25x25mm; 1mm slice thickness; 9 slices; 10 frames; 3 averages and acquisition time = 8 minutes. ECG triggering and respiration gating were used for the T2* weighted acquisition, while only ECG triggering was applied for cine-FLASH imaging.

Results

In all animals, VSOP uptake was observed in the infarct zone and correlated with the presence of macrophages. An increasing severity and extent of signal attenuation due to T2* signal decay was observed in the infarct zone with increasing echo times (Figure 1). For the shortest TE (0.68ms) only a small dark area was observed at the endocardial border of the septal wall consistent with VSOP uptake and macrophage presence. Longer TEs resulted in an increase of the signal void area extending towards the epicardial borders. A pixel wise T2* map generated from the four images shows low T2* values in the infarct area. Brighter areas represent shorter T2* values. The signal void area visible on the TE=3ms image had a mean T2* of 1.1 \pm 0.2ms, while the remaining white area had a T2* value of 2.5 \pm 0.3ms. The mean EF in these mice was 40 \pm 3%.

Discussion & Conclusion

The combined use of a very small iron-oxide particle, VSOP, and the use of short to long TE acquisition to generate T2* mapping allowed the quantitative assessment of VSOP uptake in the infarct zone, which was in good agreement with the presence of macrophages. This approach may be useful to quantify the severity of inflammation post myocardial infarction and thus may be useful to assess therapy response post interventional or medical treatment. The T2* weighted images allowed quantification of T2* but also allowed generating positive contrast images of the inflammation areas by subtracting short and long TE images (4).

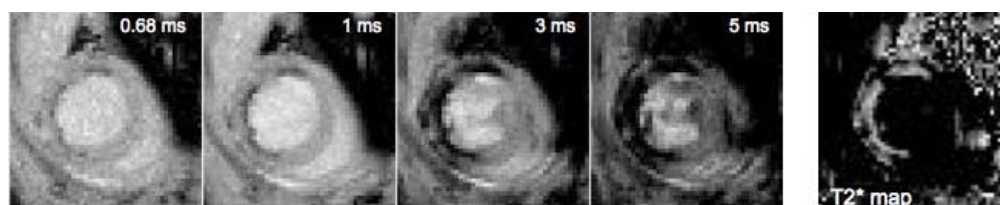


Figure 1. T2* decay is shown in 4 short axis images acquired at TE of 0.68, 1, 3 and 5 ms in the left ventricle. On the corresponding T2* map a bright area can be observed, corresponding to short T2* values and the area of myocardial infarction.

References

1. Nahrendorf M, Sosnovik DE, French BA, et al. *Circ Cardiovasc Imaging* 2009;2(1):56-70.
2. Sosnovik DE, Nahrendorf M, Deliolanis N, et al. *Circulation* 2007;115(11):1384-1391.
3. Taupitz M, Schnorr J, Abramjuk C, et al. *J Magn Reson Imaging* 2000;12(6):905-911.
4. Protti A, Herlihy A, Tessier J, et al. *The Open Magnetic Resonance Journal* 2008;2:1-7.