

# Comparison of Magnetic Resonance Imaging and Doppler Echocardiography for the Evaluation of Diastolic Function in Patients with Hypertrophic Cardiomyopathy

Y. Choe<sup>1</sup>, and E. Kim<sup>2</sup>

<sup>1</sup>Radiology, Samsung Medical Center, Sungkyunkwan University School of Medicine, Seoul, Seoul, Korea, Republic of, <sup>2</sup>Radiology, Samsung Medical Center, Seoul, Korea, Republic of

**Purpose** Diastolic function is a powerful clinical and prognostic factor in hypertrophic cardiomyopathy, but not included in the routine measurement of cardiac magnetic resonance imaging (MRI). The purpose of this study is to assess the role of MRI in the assessment of diastolic function by comparing the diastolic mitral inflow parameters using MRI and transthoracic Doppler echocardiography in patients with hypertrophic cardiomyopathy.

**Materials and Methods** Thirty-three patients (21 men and 12 women; mean age, 56 years; range, 29-74 years) who was diagnosed as hypertrophic cardiomyopathy based on echocardiographic and contrast-enhanced cardiac MRI findings were evaluated. Phase-contrast MRI images of mitral inflow were obtained in the left ventricle to quantify diastolic blood flow. MRI measurements of diastolic parameters were compared (Spearman's rho correlation) with echocardiographic parameters.

**Results** Blood flow in the mitral valve was successfully imaged by MR for all patients (33/33, 100%) while transthoracic echocardiography could measure flow in 30 of 33 (91%) patients. For the 30 patients, early diastolic (E) peak velocity was  $65 \pm 18$  cm/s using MRI versus  $72 \pm 25$  cm/s using echocardiography (Spearman's rank correlation 0.74,  $P = 0.000$ ), and late diastolic (A) peak velocity was  $68 \pm 21$  cm/s using MRI versus  $71 \pm 23$  cm/s using echocardiography (Spearman's rank correlation 0.84,  $P = 0.000$ ). E/A ratio was  $1.05 \pm 0.6$  using MRI and  $1.1 \pm 0.6$  using echocardiography (Spearman's rank correlation 0.60,  $P = 0.001$ ). Deceleration times in both modalities showed good correlation (MRI,  $244 \pm 80$  ms vs echocardiography,  $232 \pm 80$  ms; Spearman's rank correlation 0.47,  $P = 0.008$ ).

**Conclusion** Mitral inflow peak velocity parameters measured using phase-contrast MRI in patients with hypertrophic cardiomyopathy showed good correlation with echocardiography.

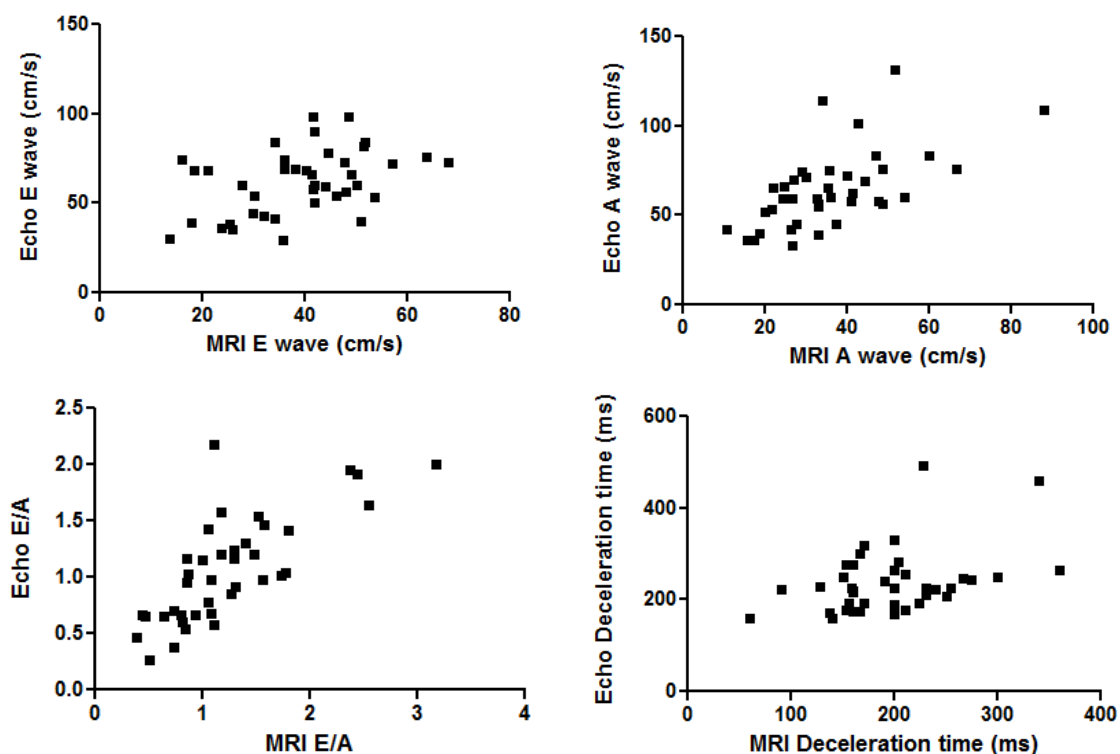


Figure 1. Graphs show the correlation of mitral inflow parameters of echocardiography and MRI.