

## High Resolution MRI of the Plantar Plates in Patients with Rheumatoid Arthritis

H. J. Siddle<sup>1</sup>, A. J. Grainger<sup>2</sup>, A. C. Redmond<sup>1</sup>, P. S. Helliwell<sup>1</sup>, R. J. Wakefield<sup>1</sup>, and R. J. Hodgson<sup>3</sup>

<sup>1</sup>Section of Musculoskeletal Disease, University of Leeds, Leeds, United Kingdom, <sup>2</sup>Department of Radiology, Leeds Teaching Hospitals NHS Trust, Leeds, United Kingdom, <sup>3</sup>Leeds Musculoskeletal Biomedical Research Unit, University of Leeds, Leeds, United Kingdom

### Introduction:

Forefoot pain and deformity at the metatarsophalangeal (MTP) joints is commonly reported in patients with rheumatoid arthritis (RA), however the structures involved and mechanisms leading to MTP joint changes have not been clearly identified. Dysfunctions of periarticular structures such as the plantar plate have been widely reported to lead to structural instability and morbidity in the forefoot. Previous research has suggested that forefoot deformities in RA might result from the failure of a complex ligamentous system and the dynamic effect of displacement of the plantar plates<sup>1</sup>. Magnetic Resonance imaging (MRI) has been shown to be effective for identifying the plantar plate and visualising tears in otherwise healthy subjects. A hyperintense region at the insertion is often interpreted as a tear<sup>2</sup>; however, this has not been investigated in patients with RA. The aim of this study was to use high-resolution 3T MRI to investigate the plantar plates of the lesser (2<sup>nd</sup> to 5<sup>th</sup>) MTP joints in patients with RA.

### Method:

In 17 patients (11 females: 6 males; mean age 56.6 years) with RA the more symptomatic forefoot was imaged at 3T using an eight-channel knee or wrist coil. Proton density fat-suppressed sequences (TR3500, TE35, 0.5x0.3 mm in-plane resolution, 3mm slices) were acquired in the sagittal plane and T2 weighted fat-suppressed sequences (TR4100, TE92, 0.5x0.3 mm in-plane resolution, 3mm slices) were acquired in the sagittal and axial planes through the MTP joints of 68 lesser MTP joints (Figure A). The images were read by two experienced consultant musculoskeletal radiologists and a consensus was reached. The images were assessed to determine the presence or absence of the plantar plate, tears (loss of continuity) of the plantar plate, whether the tear was partial or full width, and whether high signal was present at the insertion on T2 weighted images.

### Results:

At least one of the plantar plates of the lesser MTP joints was torn or absent in all 17 patients.

One or more of the plantar plates were absent in 8 patients (Figure C). The plantar plate was absent at the 5<sup>th</sup> MTP joint in 6 patients, and all plantar plates were absent in one patient.

Tears in the plantar plate were identified in 15 patients (88%). Tears were observed in 28 out of 68 (41.2%) plantar plates (4 in the 2<sup>nd</sup>, 5 in the 3<sup>rd</sup>, 9 in the 4<sup>th</sup> and 10 in the 5<sup>th</sup> plantar plate). 6 (21.4%) tears were full width (Figure B) and the majority of partial tears (71.4%) were located medially.

High signal was seen in 23 (33.8%) plantar plates at the insertion. A tear was seen in only 10 of these plantar plates; in the remainder the plantar plate was continuous with the proximal phalanx. Tears were reported in 17 plantar plates despite the absence of high signal at the insertion.

### Discussion:

Plantar plate tears are common at the lesser MTP joints of patients with RA and forefoot pain. Tears and absence of the plantar plate are commonest at the 5<sup>th</sup> MTP joint, which is consistent with the distribution of RA in the forefoot. This study suggests that forefoot pain and deformity seen in patients with RA is associated with plantar plate tears. However this study does not establish whether tears in the plantar plate are the cause of forefoot pain and further investigation is required.

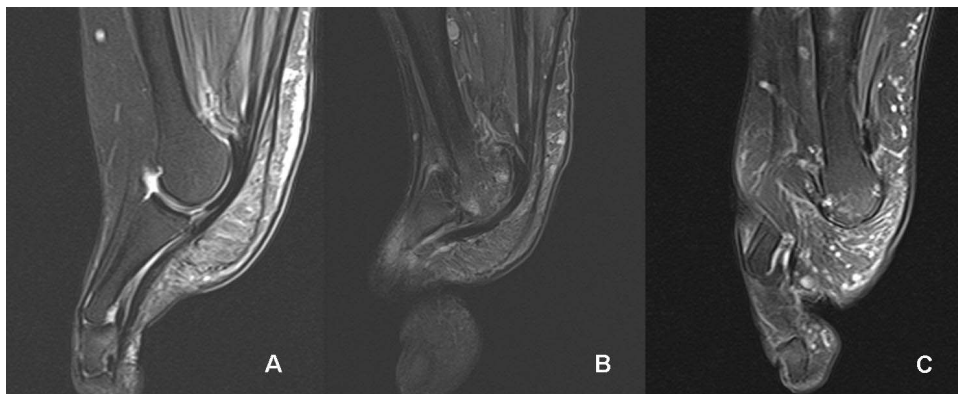
High signal at the insertion does not appear to be a reliable indicator of the presence of a tear in patients with RA, unlike other patient groups. The high signal may be the result of synovitis or effusion typically seen at the MTP joints in RA, rather than the result of a tear. The high signal does increase the conspicuity of the plantar plate at the insertion.

In conclusion, plantar plate damage is common in RA and well demonstrated by high resolution MRI.

### References:

1 Stainsby, G.D., Pathological anatomy and dynamic effect of the displaced plantar plate and the importance of the integrity of the plantar plate-deep transverse metatarsal ligament tie-bar. *Annals of the Royal College of Surgeons of England*, 1997. 79(1): p. 58-68.

2 Gregg, J., et al., Sonographic and MRI evaluation of the plantar plate: A prospective study. *European Radiology*, 2006. 16(12): p. 2661-9.



**Figure A:** An intact plantar plate showing continuity with the proximal phalanx. The plantar plate is relatively thin at the insertion, a normal finding.

**Figure B:** A full width tear of the plantar plate. There is a large gap between the distal part of the plantar plate and the proximal phalanx.

**Figure C:** Absent plantar plate.