

# EVALUATION OF CARTILAGE T2 USING LOADING IN SITU MRI IN PATIENTS WITH KNEE INJURIES

T. Nishii<sup>1</sup>, T. Shiomi<sup>2</sup>, H. Tanaka<sup>3</sup>, K. Nakata<sup>2</sup>, K. Murase<sup>4</sup>, Y. Yamazaki<sup>4</sup>, H. Yoshikawa<sup>2</sup>, and N. Sugano<sup>1</sup>

<sup>1</sup>Department of Orthopaedic Medical Engineering, Osaka University Medical School, Osaka, Japan, <sup>2</sup>Department of Orthopaedic Surgery, Osaka University Medical School, <sup>3</sup>Department of Radiology, Osaka University Medical School, <sup>4</sup>Department of Medical Physics & Engineering, Osaka University Medical School

## Introduction

The articular cartilage in the knee joint provides load-bearing function along with adjacent meniscus and anterior/posterior cruciate ligaments, and injury of the meniscus, cruciate ligaments and articular cartilage may result in failure in responding to normal load-bearing. Previous clinical studies showed that 80% or more patients with injury of anterior cruciate ligaments resulted in development of knee osteoarthritis within follow-up of 10 years, presumably due to sustained intra-articular mechanical disorder [1]. Therefore, evaluation of intra-articular biomechanical condition after knee injury is important to estimate risk of subsequent progression of osteoarthritis and decided appropriate treatment methods. Recent studies of MR imaging showed cartilage T2 is closely related with cartilage matrix and water content. Responsiveness of articular cartilage to compressive loading by T2 may indicate pressure distribution on the cartilage, via evaluation of dynamic changes in the collagenous architecture or water influx or efflux through cartilage [2]. We have developed a loading apparatus to apply axial load to the knee joint during MR imaging in order to simulate physiological load-bearing condition while standing. Our objectives were to examine clinical feasibility of cartilage T2 with use of loading in situ MR imaging, for evaluation of abnormal pressure distribution in patients with knee injuries, especially focusing on meniscus tear.

## Materials and Methods

Nine patients with knee injuries (9 knees) and 4 asymptomatic normal volunteers (4 knees) were imaged on a 3.0 T MRI scanner (GE Healthcare, WI) using a 8-channel knee phased array coil. There were 8 men and 5 women, and the mean age of the patients and volunteers were 32 and 33 years, respectively. Among 9 patients, 3 knees had injury of anterior cruciate ligament (ACL), one knee had injury of posterior cruciate ligament (PCL), 4 knees had injury of both ACL and meniscus, and one knee had meniscus injury. After MR imaging, all patients received arthroscopic surgery and definite diagnosis was obtained. All participants provided informed consent to participate in the study, which was approved by the Institutional Review Board.

During MR imaging, the participants were laid on a custom-made loading apparatus, which had a pulley system linked to a sliding foot plate. The shoulders of the participants were strapped tightly, and 50% of the body weight was applied via the foot plate, when loading. On unloading and loading conditions, sagittal T2 maps of the medial and lateral femoro-tibial joints were obtained from multi-echo spin echo sequence with fat-suppression (TR, 1500 ms; 8 echoes between 10.0 ms and 80.0 ms; field of view, 12 cm; matrix, 384 × 256; slice thickness, 3 mm; signal averaging, 1). T2 value was calculated on a pixel-by-pixel basis by fitting the echo time data and the corresponding signal intensity to a mono-exponential equation.

On each of medial and lateral mid-sagittal image, the cartilages at the weight-bearing ranging anterior and posterior margins of the meniscus were divided into 3 sections with equal length (anterior/mid/posterior), and each section was further divided into deep and superficial layers with equal thickness, using a custom-made software (Fig 1). Change of T2 values by loading in each ROI was compared between patients with knee injuries and normal volunteers and between joint compartments with and without meniscus tear, using the nonparametric Mann-Whitney U test.

## Results

On unloading condition, there was no significant difference of T2 at each ROI between patients and volunteers, except AD of the medial femoral cartilage in which T2 of the patients was significantly higher ( $p=0.01$ ).

By loading, T2 was likely to decrease at each zone, compared to unloading condition; T2 at MS of the lateral femoral cartilage decreased significantly larger in volunteers than patients ( $-6.7\%$  vs  $+2.4\%$ ,  $p<0.05$ ).

Among all 14 subjects, meniscus tear was noted in 4 of 9 knees at the medial side, and in 4 of 9 knees at the lateral side. In the medial side, T2 at AS decreased significantly larger in knees without meniscus tear than knees with meniscus tear ( $-8.6\%$  vs  $+1.7\%$ ,  $p<0.05$ ) (Fig 2). In the lateral side, there was no significant difference of T2 decrease between knees with and without meniscus tear.

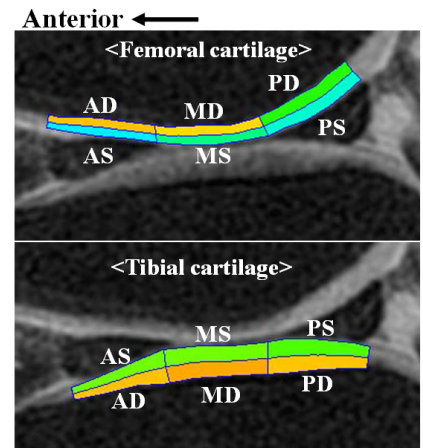
## Discussion

With application of loading system, we found tendency of decreases in cartilage T2 values. This finding of decreased T2 in response to compressive loading is consistent with previous experimental and clinical studies, and has been accounted for by deformation of cartilage architecture, extrusion of water content, and relative increase of proteoglycan and collagen content within the cartilage [2-4].

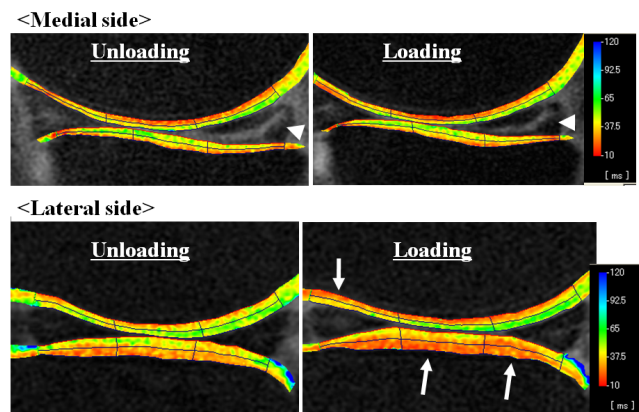
The meniscus has important mechanical role of the load-bearing function. In cadaveric studies, the compressive load transmitted through the meniscus was greater than the compressive load on the uncovered cartilage, and the meniscus was assumed to distribute the load transmission over the entire surface of the tibial cartilage [5]. In the femoral cartilage, the present results showed significantly smaller decrease of T2 in knees with meniscus tear. Assuming that decrease of T2 is correlated with amount of compressive loading, this finding may reflect location-specific load transmission failure associated with the meniscus tear. In this context, T2 evaluation under loading conditions can be expected to provide biomechanical assessment of pathological conditions with respect to localized stress concentration in the cartilage of patients with knee injuries.

## References

- [1] Lohmander LS, et al. Arthritis Rheum, 2004. [2] Kaufman JH, et al. J Magn Reson Imaging. 1999. [3] Grunder W, et al. Magn Reson Med 2000. [4] Nag D, et al. J Magn Reson Imaging 2004. [5] Walker PS, et al. Clin Orthop Relat Res 1975.



**Fig1:** Zonal definition of the femoral and tibial cartilages: Superficial layer (AS,MS,PS) and deep layer (AD,MD,PD)



**Fig2:** Cartilage T2 maps on mid-sagittal images in a patient with medial meniscus tear. On the medial side with meniscus tear (arrow head), no significant decrease of T2 was shown by loading (upper row). On the lateral side with intact meniscus, significant decrease of T2 was shown by loading (arrows, lower row)