

Towards a dedicated dGEMRIC protocol for biochemical imaging of the menisci: Gd-DTPA(2-) enhancement kinetics in the menisci of asymptomatic subjects

M. E. Mayerhoefer¹, G. Riegler¹, T. C. Mamisch², G. H. Welsch¹, M. Weber¹, S. Apprich¹, and S. Trattnig¹

¹Department of Radiology, MR Center, Medical University of Vienna, Vienna, Austria, ²Inselspital Bern, Switzerland

INTRODUCTION

T1 mapping after delayed gadolinium enhancement (dGEMRIC) is a well-accepted biochemical MRI technique for the quantitative evaluation of the glycosaminoglycan concentration of cartilage tissue (1). For evaluation of articular cartilage, dGEMRIC is performed 90 minutes following contrast media (CM) administration, because this is the time interval required to reach equilibrium distribution of Gd-DTPA²⁻ within cartilage tissue (2). For meniscal tissue, however, it is unclear whether such an equilibrium phase exists, how long it takes to reach it, and how long it lasts. This knowledge is important, however, because it is the basis for the development of a dedicated protocol for dGEMRIC of the menisci. Therefore, it was the aim of the present study to investigate the contrast enhancement kinetics within the menisci of the knee joint over a prolonged period of time.

MATERIALS AND METHODS

We enrolled six asymptomatic volunteers (4 men and 2 women; mean age, 26.1 ±5.3 years) without the presence, or a history of, meniscus damage or surgery in our study. Sagittal T1-weighted spin-echo sequences of the knee joints were obtained using a 3.0 Tesla MR scanner (Magnetom Trio; Siemens, Erlangen, Germany) with a gradient strength of 40 mT/m, equipped with a dedicated flexible eight-channel knee array coil (Noras, Wuerzburg, Germany). Imaging was performed before (baseline), and then in half-hour intervals over a period of 9 hours after intravenous administration of 0.2 mmol/kg Gd-DTPA²⁻. Regions of interest (ROIs) were manually defined by a senior board-certified musculoskeletal radiologist on each of two adjacent sections, of the anterior and posterior horns of the medial and lateral meniscus, respectively. Each ROI was further subdivided into a peripheral zone (outer one-third of the meniscal horn, corresponding to the vascularized “red zone”), and a central zone (inner two-thirds of the meniscal horn, corresponding to the moderately vascularized “intermediate zone”, and the avascular “white zone”). Special care was taken to ensure that sites and ROI positions were identical between the different measurements. Mean signal intensities of the ROIs were measured at each time point. Rates of enhancement relative to baseline (unenhanced scan) were calculated and enhancement curves were constructed. Two-way repeated measures ANOVA was used for group comparisons. The specified level of significance was 5%.

RESULTS

For both central and peripheral zones, we observed the strongest enhancement, relative to baseline, between 3 and 4 hours after CM application (Fig. 1, 2). ANOVA revealed no significant difference ($p=.94$) between these three time points (3; 3.5; and 4 hours post CM administration) in terms of enhancement, for peripheral as well as central zones. There was also no significant difference between time points from 2.5 to 4.5 hours post CM application ($p=.14$). We did, however, observe significant differences between time points from 2 to 5 hours ($p=.014$). In the peripheral zones of the menisci, the enhancement generally occurred more rapidly than in the central zones, and subsequently also decreased more rapidly (Fig. 2).

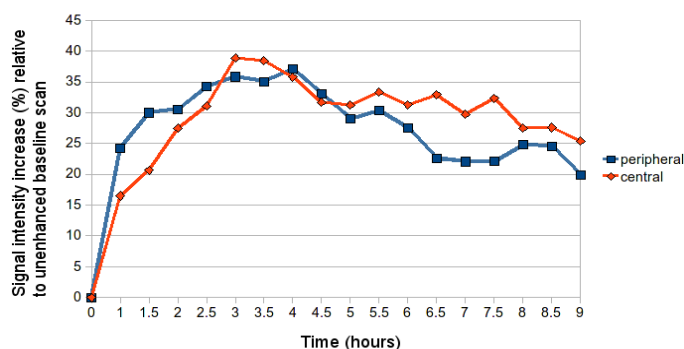


Fig. 1: Enhancement curves for peripheral and central zones of the menisci, following intravenous injection of Gd-DTPA²⁻.

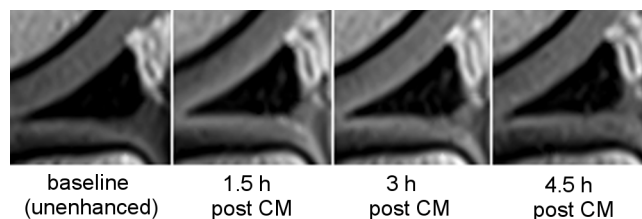


Fig. 2: Contrast enhancement in the posterior horn of the lateral meniscus of a healthy 23 year-old male volunteer. The maximum enhancement, which is particularly well-visible in the periphery, occurs 3 hours post CM application.

DISCUSSION

In meniscal tissue, the peak enhancement after Gd-DTPA²⁻ administration occurs considerably later than in articular cartilage of the knee joint (3 hours vs. 1.5 hours, respectively), and remains constant for a relatively short period of time. In the peripheral zones of the menisci, CM uptake occurs faster than in the central zones, probably due to the direct vascularization of the peripheral zone. This theory is supported by the fact that CM washout also occurs faster in the peripheral zones. The time window suitable for dGEMRIC imaging of the menisci approximately lies between 3 and 4 hours post CM injection.

REFERENCES

1. Link TM, Stahl R, Woertler K. Cartilage imaging: motivation, techniques, current and future significance. *Eur Radiol.* 2007;17:1135–1146.
2. Burstein D, Velyvis J, Scott KT, et al. Protocol issues for delayed Gd (DTPA)(2-)-enhanced MRI: (dGEMRIC) for clinical evaluation of articular cartilage. *Magn Reson Med.* 2001;45:36–41.