

Developmental Changes in the Shape of Hippocampus in Children Aged from 6 to 9 Years Old

M. Lin¹, L. T. Muftuler¹, K. Nie¹, K. Head¹, C. Buss², E. P. Davis², C. A. Sandman², O. Nalcioglu¹, and M-Y. L. Su¹

¹Tu & Yuen Center for Functional Onco-Imaging, University of California, Irvine, Irvine, CA, United States, ²Department of Psychiatry and Human Behavior, University of California, Irvine, Irvine, CA, United States

Background and purpose:

The shape analysis of hippocampus was developed to investigate the progression of atrophy pattern in elderly patients with mild cognitive impairment and Alzheimer's disease compared to healthy age-matched controls. Two different approaches were reported before - one by mapping the surface contour of the hippocampus onto a 2-D grid map, and the other by comparing the extent of transformation for each individual hippocampus to match to a standard template using non-rigid coregistration algorithms. The 2-D grid method has been applied to evaluate the development of hippocampus from 4 to 25 years old [1]. In this work we applied the same technique to children from 6 to 9 years old to investigate whether there is a significant change within this narrow age range.

Methods:

48 MRI studies were analyzed. The MRI was performed using a Phillips Achieva 3.0T scanner. These children were selected from a cohort from 6 to 9 years old (22 males/26 females). For age comparison, the subjects were divided into two groups based on different age ranges: 6-7 yo (N=36) vs. 8-9 yo (N=12). The hippocampus was manually outlined on T1-weighted anatomic images by one well-trained operator, using a protocol developed by the Montreal Neurologic Institute based on a standard brain template. The brain image of each individual child was first co-registered to the template using SPM. The hippocampi were manually delineated bilaterally by the operator blind to gender, age, scan order and hemisphere. The manually outline hippocampus on the template were used for the shape analysis, that is, the difference of the brain size has been controlled. To analyze the shape of hippocampal contour, anatomical mesh modeling methods [2] were used to match equivalent hippocampal surface points of each subject. The centerline of hippocampus was first extracted using a level-set based algorithm [3] and the whole hippocampus was divided into 150 slices, by uniformly segmenting each slice perpendicular to the centerline with equal thickness. The hippocampus was further separated into two hemispheres (anterior and posterior) for separate analysis. For each segmented slice from a hemisphere, 100 surface points were uniformly assigned along the boundary. In total, there are 15,000 digitized points representing the hippocampal surface from each hemisphere. Using this method, the spatial frequency of digitized points representing the hippocampal surface can be equalized within and across brain slices, which enables the normalized comparison between different subjects. The distance from each surface point to the centerline was calculated and recorded into a 150×100 matrix. Fig.1a shows the radial distance mapping of the surface points. Fig.1b shows hippocampi from two individual subjects, a 6 yo and a 9 yo. The distance matrix for each hippocampus was calculated for statistical analysis. The permutation test and the student's t test were applied to evaluate the significance of difference at each surface point (or, each point on the 2D grid map) between the two groups. The threshold for significant difference was set at $p < 0.05$. In permutation test, each p value was obtained from 10,000 iterations. The least-squared quadratic regression model [1] was also used to test the correlation between radial distance and age (continuous variable using months) by fitting the radial distance at each surface point. The significance map was displayed on a template generated from these 48 subjects, by averaging the coordinates of each surface point across all subjects, shown in Fig.2. The color bar indicates the p value obtained using 3 statistical analyses.

Results:

Figure 2 shows the p values between 6-7 vs. 8-9 years old analyzed using permutation test (Fig.2a), t-test (Fig.2b), and the regression analysis with age (Fig.2c). The results analyzed using the permutation test (L: 0.4597 +/- 0.0287, R: 0.4638 +/- 0.0381) and Student's T test (L: 0.4320 +/- 0.0326, R: 0.4647 +/- 0.0385) were consistent, showing similar color-coding patterns in the significance maps. The difference appears in part of CA1 and subiculum. The results analyzed using the quadratic regression model (L: 0.5344 +/- 0.0324, R: 0.5150 +/- 0.0365) indicate that radial distance is not correlated with age in most area of hippocampus. Only a small region showing highly significant differences in the group comparison remains significant in the regression analysis. Two examples from 6 and 9 years old shown in Fig. 1 suggest that the overall shape of hippocampus is similar. The group comparison results will be dependent on the choice of the cut-off age; and the regression analysis results are more reliable.

Discussion:

This is an exploratory study to investigate the difference in the shape of hippocampus in children within a narrow age range. The results show that there may be a subtle difference when comparing the younger group (6-7 years old) to the older group (8-9 years old) in CA1 and subiculum. However, the regression analysis shows that the area with significant difference is very small. Overall, based on this small series, the shape of hippocampus within this age group does not show a strong age dependence. The observed differences are mostly likely coming from differences in the individual brain. The hippocampus analyzed in this work was outlined based on co-registered images to a template, so the difference in the brain size has been accounted for. A separate analysis based on the hippocampus outlined on individual brain is needed to evaluate whether the registration introduces local deformation that may distort the shape, thus affect the comparison results.

Reference: [1] Gogtay et al. Hippocampus 2006;16:664-672. [2] Thompson et al. Neuro Image 2004;22:1754-1766. [3] Telea et al. ACM Int Conf Proc 2003;40:185-194.

Acknowledgement: This research is supported in part by NIH R01 HD050662 and NIH R01 HD-48947.

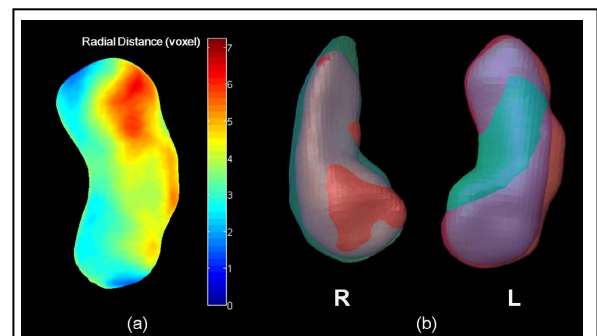


Fig.1 (a) Color coding of radial distance on hippocampus to the center line. (b) Overlay of two individual hippocampi from a 6 yo (red) and a 9 yo (cyan). Purple denotes the overlapped volume between the 2 subjects.

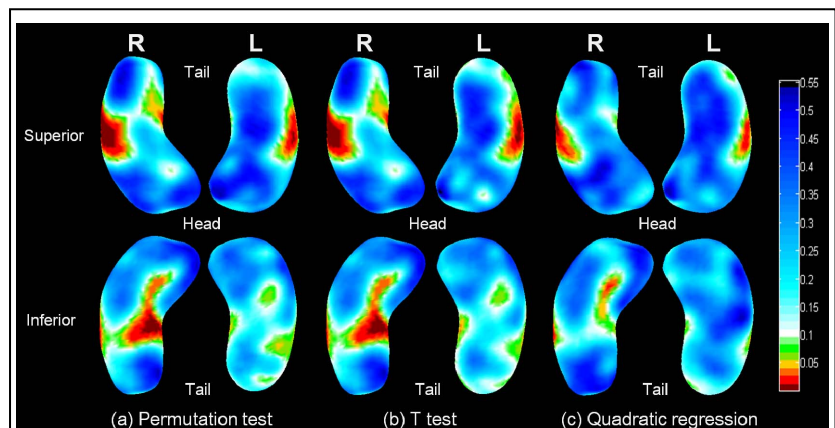


Fig.2 Color-coded significance maps. The orange color represents the significant level at p=0.05. (a) p value calculated using the permutation test. (b) p value calculated using Student's t test. (c) p value calculated using the least-squared quadratic regression model to analyze the dependence with age (months).