

## Visualizing RF ablation lesions real-time at 3Tesla

S. Vijayakumar<sup>1,2</sup>, E. G. Kholmovski<sup>1</sup>, G. Payne<sup>1</sup>, J. Blauer<sup>3</sup>, C. Gloschat<sup>3</sup>, J. H. Davis<sup>4</sup>, R. MacLeod<sup>3,4</sup>, K. Lilbok<sup>5</sup>, G. Vergara<sup>5</sup>, M. Guttman<sup>6</sup>, K. Vij<sup>6</sup>, C. J. McGann<sup>2,7</sup>, D. L. Parker<sup>1</sup>, and N. F. Marrouche<sup>5</sup>

<sup>1</sup>UCAIR, Department of Radiology, University of Utah, Salt Lake City, Utah, United States, <sup>2</sup>CARMA Center, University of Utah, Salt Lake City, Utah, United States, <sup>3</sup>Dept. of Biomedical Engineering, University of Utah, Salt Lake City, Utah, United States, <sup>4</sup>CVRTI, University of Utah, Salt Lake City, Utah, United States, <sup>5</sup>Dept. of Cardiology, University of Utah, Salt Lake City, Utah, United States, <sup>6</sup>Surgivision Inc, Irvine, California, United States, <sup>7</sup>Drpt. of Cardiology, University of Utah, Salt Lake City, Utah, United States

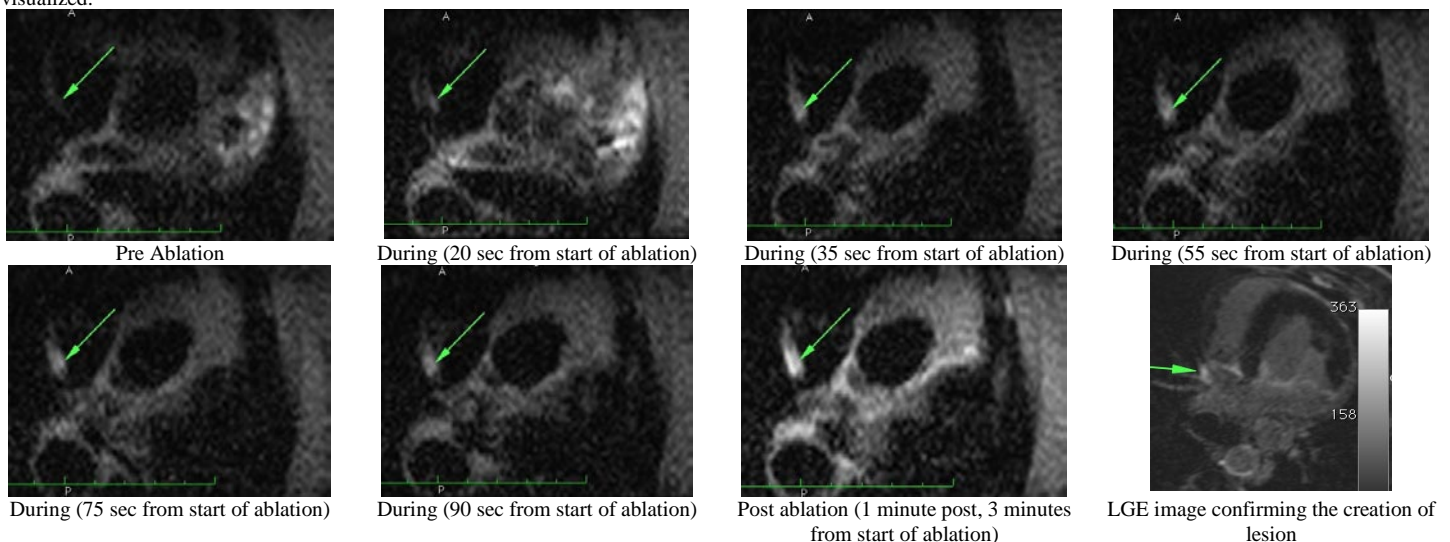
**Introduction:** Radio frequency (RF) ablation of the left atrium (LA) and pulmonary vein (PV) ostia has become a clinically acceptable therapy for atrial fibrillation (AF) [1,2]. Currently, this interventional procedure is performed under x-ray fluoroscopy and the associated radiation burden provides strong motivation for alternative imaging approaches. With the advent of improved magnetic resonance imaging (MRI) sequences to visualize post ablation scar and assess treatment outcome [3,4], MRI offers a promising alternative to guide and assess these RF ablations. Previous studies [5,6] have shown the use of MRI compatible RF ablation catheters and performed ablation under MRI. Non-contrast and late gadolinium enhancement (LGE)-imaging techniques were used to assess and characterize lesions in the ventricle and atrium. In [7], a non-contrast enhanced MRI technique to characterize sub-acute (30 minutes or longer) RF ablation lesions on a canine model was described. RF ablations were performed on the epicardial surface of the ventricle using standard clinical catheters and RF generator outside the MRI scanner, and lesions were assessed using non-contrast MRI.

**In this work, we present the results of MR-guided RF ablation performed in the atria of pigs and the visualization of lesions as they formed during ablation under MRI.**

**Methods:** Five porcine experiments were performed with each of the animals weighing about 40kg. All pigs were treated subcutaneously with a 12F introducer sheath placed in the right femoral vein to enable a trans-septal puncture to get into the left atrium and then insert an MR compatible ablation catheter. All animal protocols were reviewed and approved by the local IACUC. The animal vitals of heart rate, oxygen saturation, carbon dioxide expulsion and arterial blood pressure were all monitored. All ablations were performed using the Stockert RF generator (Biosense Webster) with MR compatible interface circuits, custom built for 3 Tesla magnetic fields. All imaging was performed using the body and spine array coils on a 3T Siemens Verio scanner (Siemens Healthcare, Erlangen, Germany).

Two of the 5 animals, could not be revived despite defibrillation in the MRI environment (so, there were no corresponding LGE images). One of the remaining 3 pigs also went into ventricular tachycardia during the study but was quickly revived by defibrillation in the MRI room and survived the complete study. All images during the ablation procedure were acquired using either a novel Inner Volume Acquisition (IVA) dark-blood prepared 2D HASTE or dark-blood prepared TSE sequence with the following parameters - TE: 79/65; TR: 350/1910, Slice thickness: 4/4; resolution: 0.67x0.67. RF power was delivered in the bore of the scanner with the use of a real-time navigation system [8] to guide the catheter to the point of interest. During RF power delivery, images were acquired using the above-mentioned sequences to visualize lesions as they were created. Figure 1 shows a set of sample images with the RF energy delivered and the lesions being formed during delivery. After lesion visualization, contrast was injected and LGE imaging performed. The animals were then euthanized and the heart excised for visual examination of the lesions, and ex-vivo imaging at 3T to confirm the lesion visualization.

**Results:** Figure 1 shows a sample of the images acquired from one study. RF power of 20 Watts was delivered for a duration of 2 minutes in the lateral wall of the right atrium. Pre, during and post ablation images were acquired with the IVA-HASTE sequence with parameters as described above. Double dose of contrast 0.2 mmol/kg, Multihance (Bracco Diagnostic Inc., Princeton, NJ) was injected and LGE images were acquired about 15 minutes post injection to confirm that the created lesion was visualized.



**Conclusion/Discussion:** In this work, we have shown that lesions can be visualized without contrast injection, using T2-weighted sequences, as they are being formed during ablation in the MRI scanner. Also with the new IVA HASTE sequence, the respiratory motion is frozen because of the fast acquisition, providing another advantage over conventional imaging techniques. With the improvements in real-time imaging systems, catheter tracking and better MR compatible hardware, imaging lesions as they form without contrast is a significant step towards MRI-guided real time RF ablation.

Although we were able to repeat this result consecutively in 3 of the 5 experiments performed, it could not be visualized at all locations. Some of the challenges encountered were getting a proper ECG gating, the lack of a feedback system to let us know if the catheter was actually delivering power to atrium wall or blood, and improvements yet to be made in the catheter hardware. Future work will optimize the protocol to achieve consistent repeatability of lesion visualization as they form with the use of improved hardware.

### References:

1. Haissaguerre M et al. *N Engl J Med* 1998; 339:659-666.
2. Cappato R et al. *Circulation* 2005; 111:1100-1105.
3. Peters D. et al. *Radiology* 2007; 243:690-695.
4. McGann CJ et al. *JACC* 2008; 52(15):1263-1271.
5. Schmidt et al. *Circulation Arrhythmia & Electrophysiology* 2009.
6. Vijayakumar S et al. *ISMRM* 2008, Hawaii.
7. Dickfeld et al. *Heart Rhythm Society* 2007; 4(2): 208-214.
- [8] Guttman M et al. *J Magn Reson Imaging*. 2008 Aug;28(2):538-42.

**Acknowledgements:** This study was supported in part by SurgiVision Inc. and Siemens Healthcare.