

# Feasibility of detecting radiation-induced lung injury in non-small cell lung cancer patients using hyperpolarized helium-3 MRI

R. H. Ireland<sup>1,2</sup>, O. S. Din<sup>2</sup>, J. A. Swinscoe<sup>2</sup>, E. J. van Beek<sup>3</sup>, M. Q. Hatton<sup>2</sup>, and J. M. Wild<sup>1</sup>

<sup>1</sup>Academic Unit of Radiology, University of Sheffield, Sheffield, United Kingdom, <sup>2</sup>Academic Unit of Clinical Oncology, University of Sheffield, Sheffield, United Kingdom, <sup>3</sup>Department of Radiology, University of Iowa, Iowa, IA, United States

## Introduction

Radiation induced lung injury occurs commonly after thoracic irradiation. As with SPECT [1], hyperpolarized helium-3 (<sup>3</sup>He) MRI may be a useful supplementary tool for the evaluation of lung cancer radiotherapy treatment and its side effects [2-5]. The aim of this study was to compare <sup>3</sup>He-MRI acquired from lung cancer patients before and after external beam radiotherapy (EBRT) to examine whether radiation-induced changes in human lungs can be detected by <sup>3</sup>He-MR ventilation images fused with CT.

## Methods

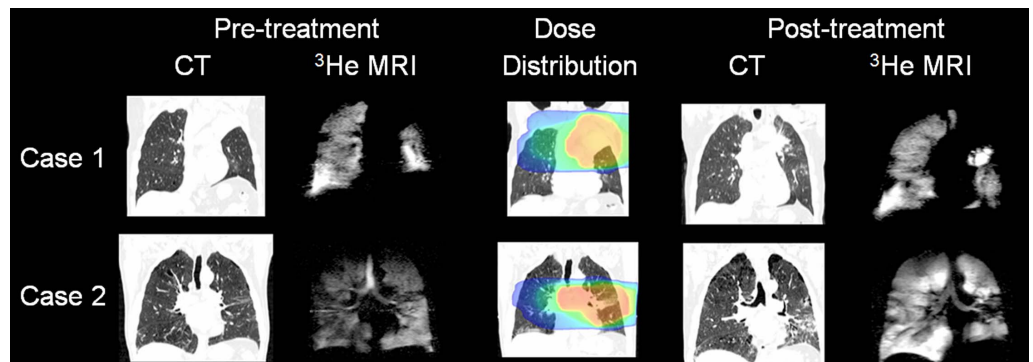
Five non-small cell lung cancer (NSCLC) patients due to have radiotherapy gave written informed consent to undergo <sup>3</sup>He MRI for a study that was approved by the Local Research Ethics Committee. <sup>3</sup>He gas was polarized on site and ventilation images were acquired during a single breath-hold of a 1L <sup>3</sup>He/N<sub>2</sub> mixture. <sup>3</sup>He MRI was performed on a 1.5T whole body Eclipse system (Philips Medical Systems), which was fitted with a second RF amplifier (2kW, Analogic Corporation). With patients in the treatment position (arms supported in the upright position), <sup>3</sup>He MRI was acquired using an elliptical birdcage coil with a 3D acquisition sequence [6] that consists of a low flip angle ( $\theta=4^\circ$ ), [96, 24] phase encodes in the [y, z] axes, 256 samples in the read encoding direction [x], 9.33mm slice thickness with no gap, FOV=42.6 cm, TE=3.25 ms, TR=6 ms, and bandwidth=31.25 kHz. Ventilation images were acquired before radiotherapy (median 13, range 4-18 days) and three months (median 100, range 41-104 days) following the end of treatment. On the same day as the initial MRI, radiotherapy planning CT was acquired on a 16 slice GE Lightspeed CT and three month CT was also available for comparison.

Pre and post treatment MR images were registered to each other and to the pre and post treatment CT. Once registered, <sup>3</sup>He-MRI was fused with the dose distribution calculated from the original treatment plan. Image registration was performed using a rigid, anatomical match point technique. Further details of the image acquisition and registration procedures have recently been reported [7].

An experienced pulmonary radiologist, who was blinded to the details of the patients and treatment, reported all the CT and <sup>3</sup>He-MRI scans. Specific quantification was given to the presence of emphysema using subjective visual grading of the lobes. The <sup>3</sup>He-MRI was automatically segmented using a threshold set at the mean plus three times the standard deviation of the background noise. Experienced radiation oncologists delineated CT lung volumes, which included the whole lung, specific lobes, the planning target volume contained within lung ('PTV in lung'), and regions of pneumonitis. The level of ventilation was then calculated as the intersection of <sup>3</sup>He-MRI and lung volume expressed as a percentage of the lung volume.

## Results

Example pre- and post-treatment images are shown for two patients. On pre-treatment images, there was a significant correlation between the degree of CT defined emphysema and <sup>3</sup>He-MRI whole lung ventilation (Spearman's rho=0.90, p=0.04). After radiation therapy, pneumonitis was evident on CT for 3/5 patients. For these cases, <sup>3</sup>He-MRI ventilation was significantly reduced within the regions of pneumonitis (pre: 94.1±2.2%, post: 73.7±4.7%; matched pairs Student t test, p=0.02, mean difference=20.4%, 95% confidence interval 6.3 to 34.6%).



## Discussion

To our knowledge, this is the first quantitative report of pre- and post-treatment longitudinal <sup>3</sup>He-MRI ventilation assessment of patients with NSCLC receiving thoracic radiation therapy. For the three patients who had signs of pneumonitis evident on CT, <sup>3</sup>He-MRI indicated a significant reduction in ventilation within the regions of pneumonitis. These observations differ from the recent work by Cai et al [8] who reported no <sup>3</sup>He-MRI ventilation changes post-irradiation. The dissimilar results may reflect the differing nature of the pre-irradiation status of lung in their set of three rabbits and in the present study of human lung cancer patients.

## Conclusions

This preliminary work demonstrates the feasibility of pre-treatment assessment of lung ventilation and post-treatment detection of radiation-induced lung damage using <sup>3</sup>He-MRI. Although statistically significant ventilation changes were found, the small sample size necessitates that these findings be validated in a larger study.

## Acknowledgments

Postdoctoral Award (UK NIHR), EPSRC, Sheffield Teaching Hospitals Research Trust, Weston Park Hospital Cancer Charity.

## References

- [1] Evans ES et al. *Semin Radiat Oncol* 17(2):72-80, 2007, [2] Ireland RH et al. *Int J Radiat Oncol Biol Phys* 68(1):273-281, 2007, [3] Sun Y et al. *Berlin ISMRM Abstract* 2869, 2007, [4] Mata J et al. *Berlin ISMRM Abstract* 1292, 2007, [5] Ward ER et al. *Int J Radiat Oncol Biol Phys* 58(5):1562-1569, 2004, [6] Wild JM et al. *Magn Reson Med* 52(3):673-678, 2004, [7] Ireland RH et al. *Phys Med Biol* 53(21):6055-6063, 2008, [8] Cai J et al. *Int J Radiat Oncol Biol Phys* 73(5):1588-1595, 2009