

7T DTI in Mild Chronic Traumatic Brain Injury: Assessment of the Superior Longitudinal Fasciculus and Cingulum Bundle

D. Cunningham¹, S. Choi¹, J. Corrigan², J. Bogner², W. Mysiw², C. R. Zachariah¹, M. V. Knopp¹, and P. Schmalbrock¹

¹Radiology, The Ohio State University, Columbus, OH, United States, ²Physical Medicine and Rehab, The Ohio State University, Columbus, OH, United States

Introduction:

Mild chronic traumatic brain injury (TBI) causes behavioral deficits without changes to standard anatomical MRI. The event of mild TBI causes axonal shearing which disrupts the highly organized bundles of nerve fibers. Diffusion tensor imaging (DTI) is sensitive to water diffusion along or across these fiber bundles. Quantitative parameters of DTI such as fractional anisotropy (FA), apparent diffusion coefficient (ADC), and fiber tractography through the entire corpus callosum and genu have already been analyzed at 7T and show promise in differentiating mild chronic TBI patients and age matched healthy controls [1]. As behavioral deficits in TBI indicate frontal brain injury, it is of significant interest to evaluate other fibers which have been implicated [2]. The objective of this study was to assess the potential of 7T DTI to analyze the superior longitudinal fasciculus (SLF) and the cingulum bundle (CB) in mild chronic TBI patients.

Methods: Seven mild chronic TBI patients with normal conventional MRI (ages 34-54y) and ten approximately age-matched healthy subjects (31-56y) were imaged at 7T (Philips, Achieva) after signing an IRB approved-informed consent. Images were acquired with a 16 channel receive coil (Nova medical), using a SE-EPI DTI sequence with TR/TE = 5126 ms/75 ms, SENSE-factor = 5, voxel size = 1.6×1.6×3.2 mm³, with b = 0, 1000 s/mm² and 6 b-directions. Diffusion tensor images were analyzed using Philips Fiber Trak with default parameter setting (FA > 0.15, angle change < 27°, fiber length > 10 mm). Analysis included tractography of the SLF and CB using the two region of interest (ROI) approach described in [3]. The estimated fiber tracts were then qualitatively evaluated for their presence, left right asymmetry, and fiber thickness. A ROI was then embedded in a mid-brain coronal slice to ensure that the quantitative parameters indeed came from the intended fiber tracts (i.e. the SLF and CB). This is important because the correct fiber may be missed when placing a ROI directly on a FA color map.

Results: Our results indicate that DTI of central and more lateral fibers in the brain at 7T is possible despite signal loss from RF inhomogeneity. Variability of the shape of the estimated tracts between subjects and hemispheres was observed for both the SLF and CB. The SLF showed a marked right left visual asymmetry. TBI patients visually showed fewer and more abnormal fibers in the right hemisphere of the SLF (Fig. 1) and in two cases the tract could not be found by the tractography algorithm. FA values from the ROI embedded in the CB showed statistically significant differences between control and TBI for both the left and right hemisphere (table). FA values from the SLF were not statistically different.

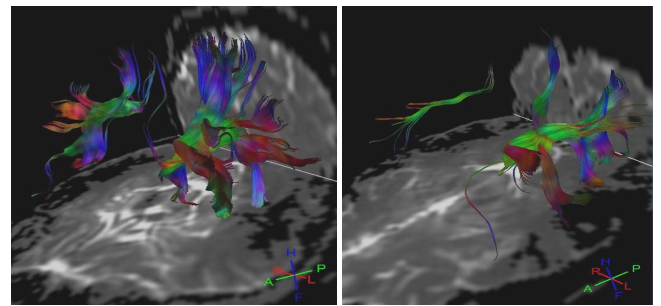


Figure 1: Tractography of a healthy control (left) and mild chronic TBI (right). Notice the left right asymmetry in control and dramatically decreased fiber thickness/density in the right hemisphere of TBI.

Discussion:

Despite magnetic field inhomogeneities at ultra high field strengths, our 7T DTI analysis showed brain diffusion abnormalities in the SLF and CB, both qualitatively and quantitatively, in TBI patients compared to healthy control subjects. Our results support the thought that chronic mild TBI is a diffuse disease of the brain. The lateral asymmetry of the SLF observed here is commonly observed in healthy subjects [5]. The visually decreased fibers or lack thereof in the right hemisphere for the SLF in TBI is an interesting finding. This shows that mild TBI has abnormal findings in multiple brain regions, thus supporting the hypothesis that DTI may be a useful tool in diagnosing and characterizing mild chronic TBI. Future studies are therefore of interest in order to further investigate this finding. While it is encouraging that fibers other than the corpus callosum can be estimated and tracked at 7T, our study has limitations, most notably of which is the suboptimal protocol used in acquiring the DTI images. The protocols used are constantly being evolved to produce higher quality images and this is a target for future work. Other future work includes focusing on more significant frontal fibers that are thought to be of specific interest in TBI such as the inferior fronto-occipital fasciculus and the anterior thalamic radiation.

References: [1] Choi et al. ISMRM 2009, 3410. [2] Niogi et al., [3] Wakana et al., 2007 NeuroImage 36: 630-644. [4] Bernal et al., 2009 epub. [5] Okada et al., 2006 Radiology 238: 668-678.

mean FA	Left			Right		
	Control	TBI	p-value	Control	TBI	p-value
CB	0.76	0.63	0.004	0.69	0.59	0.02
SLF	0.64	0.62	0.78	0.59	0.57	0.77