

BIMANUAL COORDINATION AND CORPUS CALLOSUM MICROSTRUCTURE IN YOUNG ADULTS WITH TRAUMATIC BRAIN INJURY

K. Caeyenberghs¹, and A. Leemans²

¹KULeuven, Leuven, Heverlee, Belgium, ²University Medical Center Utrecht, Netherlands

Background and objectives: Hand function is frequently affected after moderate/severe traumatic brain injury (TBI) and is treated in rehabilitation settings [1]. Bimanual actions are ubiquitous in daily life. Many coordinated movements of the upper extremities rely on precise timing of movements and interhemispheric communication via the corpus callosum (CC) [2], which is especially vulnerable to TBI [3-4]. Diffusion tensor imaging (DTI) has been shown to be an effective tool in identifying reduced fractional anisotropy (FA) in TBI patients [5-7]. However, the relationship between this tissue damage and functional performance is not well understood. The aim of this study was to investigate the relationship between white matter integrity in specific regions of the CC (i.e. genu, body, splenium, as shown in Figure 1) and performance on a bimanual coordination task.

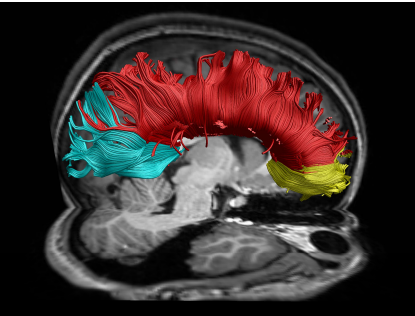


Figure 1. Corpus callosum regions of interest: splenium (cyan), body (red), and genu (yellow)

Methods: 25 adults with TBI and 18 controls (mean age = 25 y 4 mo) made spatially and temporally coupled bimanual circular motions during event-related fMRI (see Figure 2). An auditory metronome was used for pacing. There were four possible bimanual movement patterns: inward circles, outward circles, clockwise circles, and counterclockwise circles. Visual cues were used to indicate the movement to be performed. A Siemens 3 T Magnetom Trio MRI scanner (Siemens, Erlangen, Germany) with standard head coil was used for image acquisition. For all subjects, a high resolution T1-weighted structural image was acquired using magnetization prepared rapid gradient echo (MPRAGE; TR = 2300 ms, echo time (TE) = 2.98 ms, 1 x 1 x 1.1 mm voxels, field of view (FOV): 240 x 256, 160 sagittal slices). The DTI images were acquired using a DTI SE-EPI (diffusion weighted single shot spin-echo echoplanar imaging) sequence (TR/TE 7916/68 ms; matrix 96x96; FOV 220x220 mm²; parallel imaging factor 2.5; 56 contiguous sagittal slices; slice thickness 2.14 mm; voxel size 2.15x2.86x2.14 mm³). Diffusion sensitizing gradients were applied at a b-value of 1000 s/mm², along 65 non-collinear directions with one b₀ image.

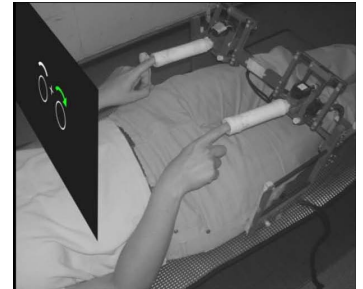


Figure 2. Task performed in the MRI scanner. Subject position and custom MRI compatible joysticks are shown.

The DTI data were analyzed and processed in ExploreDTI [8], using the following multi-step procedure: (a) Subject motion and eddy-current induced geometrical distortions were corrected [9], (b) the diffusion tensors and subsequently the FA, axial and radial diffusivity, were calculated using a non-linear regression procedure [10], (c) the DTI data were coregistered to MNI space for analyzing potential group differences [11-14], (d) a standard deterministic streamline tractography approach was used [15], to reconstruct the WM fiber pathways of interest, (e) the probabilistic cytoarchitectonic atlas [16], and a digitized version of the original Talairach atlas [17-18], both mapped in MNI space as provided by the FSL toolbox, were used to perform the correlation analysis [19]. For the kinematic and DTI measures, non-parametric Mann-Whitney U-tests were performed for comparing the group of TBI patients with the age- and gender matched control group.

Results: Bimanual task performance was significantly lower in the TBI as compared to control subjects, as shown by the larger values of the reaction time and error scores (all p 's < .01, Figure 3). Furthermore, DTI revealed a significant reduction in FA in the CC compared with the control group for all three subregions (all p 's < .001) (see Figure 3). This decrease of FA was mediated by the combined effects of axial and radial diffusivity increase (Figure 4). Bimanual performance deficits corresponded well with reductions in anisotropy. For example, duration of the contralateral disruptions (when left hand direction was involuntarily reversed during the right hand switch) correlated with mean FA in the fibers passing through in the splenium of the CC ($r = -0.53, p < .05$), in the TBI group (Figure 5).

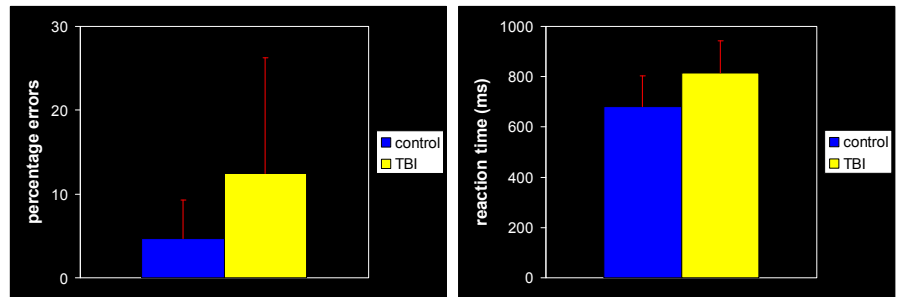


Figure 3. Mean percentage errors and reaction time for the TBI and control group.

Conclusions: This correlation between brain white matter structure and behavior, and more specifically between fractional anisotropy and motor deficits in adults with TBI, is of major interest for improving prediction of motor outcome in TBI patients. Such a prognostic tool can be used to design focused intervention protocols for TBI patients during the first months following injury.

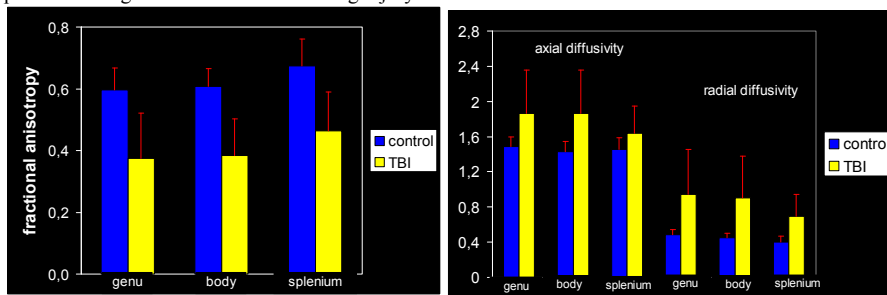


Figure 4. Diffusion parameters, mean and standard error for each ROI for both groups.

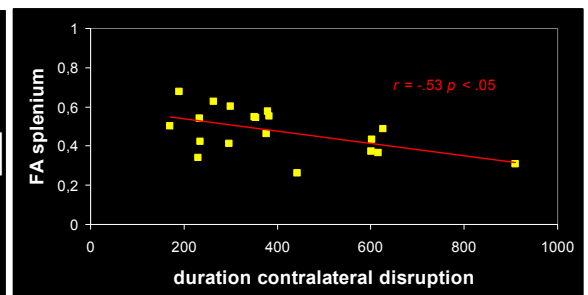


Figure 5. Scatter plot indicating the relationship between FA and bimanual performance within the TBI group. $r = -0.53, p < .05$

References. [1] Kuhtz-Bushbeck JP, et al. Dev Med Child Neurol 2003;45:821-8. [2] Swinnen SP. Nat Rev Neurosci 2002;3:348-59. [3] Kumar R, et al. Brain Inj 2009;23:675-85. [4] Rutgers DR, et al. AJNR Am J Neuroradiol 2008;29:1730-5. [5] Kraus MF, et al. Brain 2007;130:2508-19. [6] Niogi SN, et al. AJNR Am J Neuroradiol 2008;29:967-73. [7] Sidaros A, et al. Brain 2008;131:559-72. [8] Leemans A, et al. In: 17th Annual Meeting of Intl Soc Mag Reson Med, Hawaii, USA, 2009 p. 3537. [9] Leemans A & Jones DK. Magn Reson Med 2009;61:1336-49. [10] Jones DK & Basser PJ. Magn Reson Med 2004;52:979-93. [11] Leemans A, et al. Lecture notes in computer science 2005;3708:523-30. [12] Van Hecke W, et al. IEEE Trans Med Imaging 2007;26:1598-612. [13] Van Hecke W, et al. Neuroimage 2008;43:69-80. [14] Mori S, et al. Neuroimage 2008;40:570-82. [15] Basser PJ, et al. Magn Reson Med 2000;44:625-32. [16] Eickhoff SB, et al. Neuroimage 2005;25:1325-35. [17] Lancaster JL, et al. Hum Brain Mapp 2000;10:20-31. [18] Lancaster JL, et al. Hum Brain Mapp 2007;28:1194-205. [19] Smith SM, et al. Neuroimage 2004;23:S208-19.