

# Dynamic contrast-enhanced magnetic resonance imaging reveals differences in xenografts with luminal like and basal like gene expression pattern

E. M. Huuse<sup>1</sup>, S. A. Moestue<sup>1</sup>, O. Engebråten<sup>2,3</sup>, T. F. Bathen<sup>1</sup>, and I. S. Gribbestad<sup>1</sup>

<sup>1</sup>Department of Circulation and Medical Imaging, Norwegian University of Science and Technology (NTNU), Trondheim, Norway, <sup>2</sup>Department of Tumor Biology, Institute for Cancer Research, Oslo, Norway, <sup>3</sup>Oslo University Hospital, Oslo, Norway

## Introduction

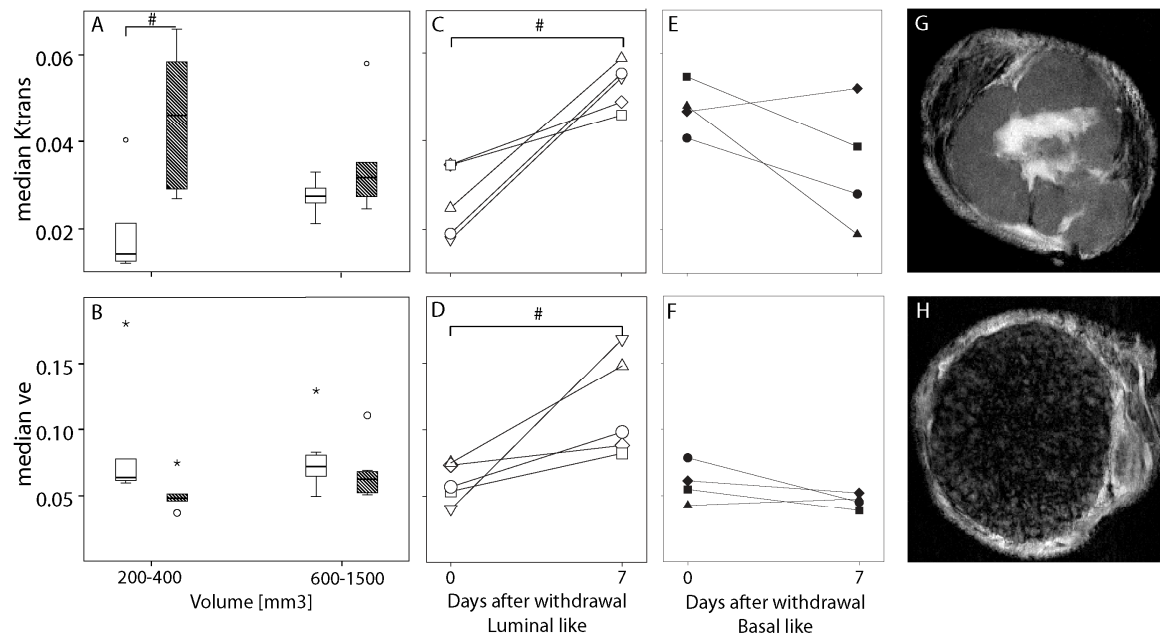
Molecular sub-classification of breast cancer based on gene expression pattern represents clinically distinct patient groups<sup>(1)</sup>. Two new breast cancer xenograft models, reflecting the basal like (MAS98.12, ER<sup>-</sup>, poor prognosis) and luminal like (MAS98.06, ER<sup>+</sup>, better prognosis) subgroups, have recently been established<sup>(2)</sup>. The purpose of this study was to characterize the two models using MRI and study the effect of tumor growth and estradiol on MR extracted parameters.

## Experimental

Tumors from MAS98.12 and MAS98.06 were orthotopically grafted in female BalbC nu/nu mice given water added estradiol (4 µg/ml). Six tumors from MAS98.12 and 5 tumors from MAS98.06 with volume 200-400mm<sup>3</sup>, and 7 tumors from each model with volume 600-1500 mm<sup>3</sup> were examined with DCE MRI using a BRUKER Biospec 7T. Precontrast T1-values were measured using a series of T1-weighted spin-echo images, followed by a dynamic sequence with 200 images with 4.8 sec temporal resolution and a voxel size of 0.32 x 0.32 x 0.6 mm<sup>3</sup>. During the 10<sup>th</sup> repetition, a dose of 0.3 mmol/kg Gadodiamide (Omniscan TM, GE Healthcare, Oslo, Norway), was injected intravenously (4 sec). T1 weighted high resolution images were obtained afterwards. For monitoring the effect of estradiol on tumor growth and MR parameters, tumors with a volume 305 ± 59 mm<sup>3</sup> (MAS98.12 n=4, MAS98.06 n=5) were imaged with the same MRI protocol. After MRI tumors were then grown without estradiol for additional 7 days, before a second MRI examination. Tofts model<sup>(3)</sup> were used for estimating K<sup>trans</sup> and v<sub>e</sub> for each voxels and voxels with poor fitting were excluded. Independent samples t-test was used for comparison of median K<sup>trans</sup> and v<sub>e</sub> between the groups with different tumour volume and between the two models. Paired samples t-test were used for comparisons before and after estradiol withdrawal.

## Results

For the small tumors, the basal like model had a significant higher K<sup>trans</sup> than the luminal like (Figure A, p<0.02). There were a slight decrease in basal like and increase in luminal like tumors when tumour volume increased, however not significant. There were no differences in v<sub>e</sub> between the two models, neither for small nor large tumors (Figure B). Basal like tumors had a significant increase in volume 7 days after estradiol removal (p<0.05), while the luminal like tumors ceased to grow. There was a significant increase in both K<sup>trans</sup> (Figure C, p<0.01) and v<sub>e</sub> (Figure D, p<0.05) in the luminal like tumors after estradiol withdrawal. For basal like tumors there were minor changes in K<sup>trans</sup> or v<sub>e</sub> (Figure E and F). The high resolution images showed clear morphological differences between the two models (Figure G and H).



**Figure:** A and B shows boxplot of median K<sup>trans</sup> in small and large tumors for both luminal (open boxes) and basal like (filled boxes) tumors. B shows analogously for v<sub>e</sub>. C and D show the progress of median K<sup>trans</sup> and median v<sub>e</sub> respectively, in luminal like tumors after estradiol withdrawal. E and F show the progress of K<sup>trans</sup> and v<sub>e</sub> respectively, in basal like tumors after estradiol withdrawal. G and H show a high resolution T1-weighted post contrast image of one luminal like and one basal like tumor respectively. #: statically significance.

## Discussion

Basal like tumors are more aggressive than luminal like, which are in accordance with the high K<sup>trans</sup> found for small tumors in basal like compared to luminal like tumors. The minor changes in the K<sup>trans</sup> and v<sub>e</sub> for the basal like tumors after estradiol removal is expected since they are estrogen receptor negative and the changes in K<sup>trans</sup> are in accordance to the effect of increased tumor volume. The increased K<sup>trans</sup> in the luminal like tumors after estradiol withdrawal might be due to reduced interstitial fluid pressure. Another reason could be stress induced angiogenesis. Furman-Haran et al showed that tamoxifen causes stress-induced angiogenesis in MCF7 xenografts<sup>(4)</sup>. In conclusion, DCE-MRI reveals differences between xenografts with different gene expression pattern.

**References:** 1) Perou CM *et al*: Nature 2000. 2) Bergamaschi A. *et al*. Mol. Oncol. 2009. 3) Tofts PS *et al*. JMRI, 1999. 4) Furman-Haran *et al*: Clin.Cancer Res. 1998.