

# Measurements of Renal Perfusion, Oxygenation, and Total Renal Blood Flow in Swine

A. L. Wentland<sup>1,2</sup>, N. S. Artz<sup>1</sup>, A. Djamali<sup>3</sup>, T. M. Grist<sup>1,2</sup>, S. B. Fain<sup>1</sup>, and E. A. Sadowski<sup>2</sup>

<sup>1</sup>Medical Physics, University of Wisconsin School of Medicine & Public Health, Madison, WI, United States, <sup>2</sup>Radiology, University of Wisconsin School of Medicine & Public Health, Madison, WI, United States, <sup>3</sup>Nephrology, University of Wisconsin School of Medicine & Public Health, Madison, WI, United States

## INTRODUCTION

Due to growing concerns regarding the development of nephrogenic systemic fibrosis [1], it has become increasingly important to evaluate MRI techniques that operate independently of gadolinium-based contrast agents. We have investigated the use of a non-contrast enhanced suite of exams in the kidneys of swine that allows for the evaluation of regional perfusion [2], regional oxygenation, and total renal blood flow. The goal of this study was to compare these measurements during pharmacologic and physiologic interventions in renal blood flow.

## MATERIALS AND METHODS

Institutional Animal Care and Use Committee approval was obtained prior to this study. Eight female swine (34-38 kg) were induced with xylazine hydrochloride (2.2 mg/kg) and telazol (7 mg/kg) and maintained for the first two hours of the experiment with propofol (10 mg/kg/hr) and fentanyl (0.0035 mg/kg/hr), followed by isoflurane (3%) for the last two hours of the experiment. A 6 French aortic catheter was placed through a femoral sheath and positioned in the suprarenal abdominal aorta for the administration of acetylcholine (4.5  $\mu$ g/kg/min) and a 450cc bolus of 0.9% normal saline. A contralateral femoral sheath was used to invasively monitor the blood pressure and heart rate. A catheter was placed in the bladder to monitor urine output.

Scans were performed on a 1.5 T MR scanner (GE Healthcare, Milwaukee, WI, USA) with an eight-element phased array torso coil. BOLD images were acquired with the following parameters: TR/TE/flip/BW = 87ms/7-41.8ms/40°/±62.5kHz, FOV = 32-34cm, and 256 x 128 matrix. Three coronal slices were acquired, each during a separate 12-second breath hold. Arterial spin labeling (ASL) perfusion images were acquired in the coronal plane with a balanced SSFP 2D imaging sequence (FIESTA) with the following parameters: TR/TE/flip/BW = 4.6ms/2.3ms/70°/±41.67kHz, FOV = 34cm, 128 x 128 matrix, NEX = 1.0, slice thickness = 8mm. Non-selective and selective inversion images were alternated until 64 total images (32 pairs) were acquired. For normalization, four proton-density images were acquired with a FIESTA readout without a prior inversion pulse. 2D Fourier-encoded phase contrast (PC) images of total renal blood flow were acquired with the following parameters: TR/TE/flip/BW = 6.7ms/3.2ms/30°/±31.25kHz, slice thickness = 5 mm, flow encoding in the superior/inferior direction, phase encoding values = 128, FOV = 24x12 cm<sup>2</sup>, and 14 phases. MR acquisitions were performed at three time points: first during baseline under the anesthetic propofol, second under the influence of acetylcholine administered in the suprarenal abdominal aorta along with a 450cc bolus of saline, and finally after two hours of the anesthetic isoflurane. After imaging, swine were euthanized with Beuthanasia-D (0.2 ml/kg).

BOLD images were analyzed as previously described by Sadowski et al [3]. ASL perfusion exams were analyzed with custom scripts written in MATLAB (MATLAB version 8.0, The MathWorks Inc., Cambridge, MA, USA). PC images were analyzed with CV Flow (Medis, The Netherlands). Measurements of average cortical perfusion, average cortical R<sub>2</sub><sup>\*</sup>, and total renal blood flow were plotted for the right kidney of each swine.

## RESULTS AND DISCUSSION

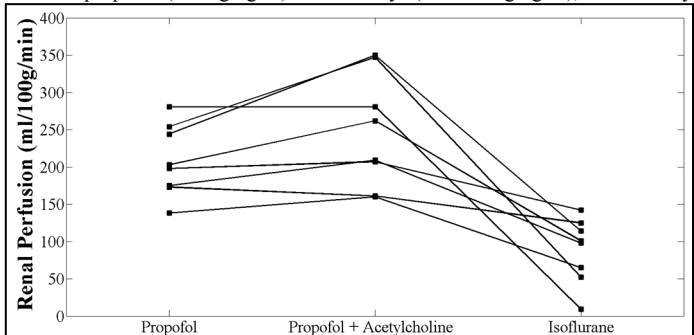
With the administration of acetylcholine and a bolus of saline, cortical perfusion increased (Figure 1), R<sub>2</sub><sup>\*</sup> decreased (increased oxygen bioavailability; Figure 2), and total renal blood flow increased (Figure 3). The opposite trend occurred after the pigs were placed on the anesthetic isoflurane for two hours. The use of acetylcholine and a saline bolus caused a moderate increase in mean arterial pressure, a moderate decrease in heart rate, and a substantial increase in urine output. The prolonged use of isoflurane anesthesia corresponded to a decrease in mean arterial pressure, heart rate, and urine output (data not shown).

## CONCLUSIONS


The fMRI measurements of cortical blood flow, cortical R<sub>2</sub><sup>\*</sup>, and total renal blood flow demonstrate expected changes with pharmacologic and physiologic maneuvers to increase renal blood flow (acetylcholine and saline) and with a pharmacologic maneuver to decrease renal blood flow (isoflurane). In future work, the effects of such pharmacologic and physiologic maneuvers must be investigated in the renal medulla.

## REFERENCES

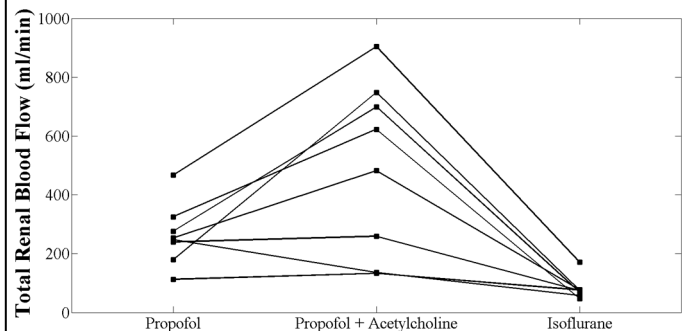
[1] Marckmann et al. J Am Soc Nephrol. 17(9): 2359-62. [2] Martirosian et al. Magn Reson Med. 51(2): 353-61. [3] Sadowski et al. Radiology. 236(3): 911-9.



**Figure 1.** Cortical renal perfusion as measured with arterial spin labeling in the right kidney of eight swine at three time points: propofol, propofol with the administration of acetylcholine and a saline bolus, and with the anesthetic isoflurane for two hours.



**Figure 2.** Cortical R<sub>2</sub><sup>\*</sup> as measured with BOLD MRI in the right kidney of eight swine at three time points: propofol, propofol with the administration of acetylcholine and a saline bolus, and with the anesthetic isoflurane for two hours.



**Figure 3.** Total renal blood flow as measured with phase contrast MRI in the right kidney of eight swine at three time points: propofol, propofol with the administration of acetylcholine and a saline bolus, and with the anesthetic isoflurane for two hours.