

Diffusion-weighted and Blood Oxygen Level-dependent MRI in Renal Tubulointerstitial Nephropathy: Initial Experience

X. Yang¹, J. Cao², and X. Wang¹

¹Department of Radiology, Peking University First Hospital, Beijing, Beijing, China, People's Republic of, ²Nephrology Department, Peking University First Hospital, Beijing, China, People's Republic of

Diffusion-weighted and Blood Oxygen Level-dependent MRI in Renal Tubulointerstitial Nephropathy: Initial Experience

Purpose

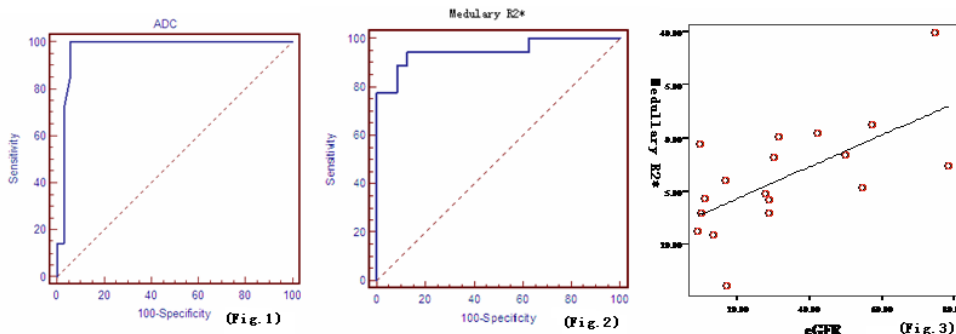
Renal tubulointerstitial nephropathy (TIN) is a complex of several clinical pathological syndromes and caused by a variety of reasons, which mainly manifests as renal sufficiency. Renal tubules and interstitial tissues are the mostly involved structures in this kind of disease. And there is no or mild primary globular injury in the course of disease. The gold standard of diagnosis is kidney biopsy, which is invasive procedure and can not reflect the disease of the medulla. Diffusion-weighted (DW) and blood oxygen level-dependent (BOLD) MRI are two newly developed functional MRI methods which can used to reflect water diffusion and tissue oxygen level in kidney respectively. The purpose of this study is to evaluate the use of DW and BOLD MRI in renal tubulointerstitial nephritis by analyzing the relationship between renal ADC value and R2* value and kidney pathology and function.

Methods

Seven biopsy-proven acute tubulointerstitial nephropathy (ATIN), and 11 chronic tubulointerstitial nephropathy (CTIN) patients were included in this study. Also 24 healthy volunteers were included as a control group. They all underwent T1WI, T2WI, DWI and BOLD MRI on a 3.0 T whole-body MR scanner (GE). Scr was tested and the eGFR were calculated according to the MDRD equation also within one week of MR scanning. The ADC and R2* values were measured by putting ROIs on anatomical templates on AW 4.2 workstation using "functool" software. The values of ADC and R2* were analyzed among the ATIN, CTIN and control group. The correlation between MRI parameters and kidney function test was analyzed too. Changes of MRI parameters were recorded when the kidney function was improved during the follow-up in ATIN group.

Results

ADC value in ATIN group (n=7) was lower than that in CTIN (n=11) and control group (n=24) ($P < 0.05$). There was no difference between CTIN and control group. Medullary R2* value in both ATIN and CTIN group were lower than that in control group, while no difference was detected between ATIN



and CTIN group. When $2.02 \times 10^{-3} \text{mm}^2/\text{s}$ was used as a cut off point for ADC value, the sensitivity and specificity for diagnosis of ATIN was 100.0% and 94.3% respectively (Fig.1). When 31.18Hz was used as a cut off point for medullary R2*, the sensitivity and specificity for diagnosis of TIN was 94.4% and 87.5% respectively (Fig.2). The medullary R2* correlated significantly with eGFR ($r=0.641$, Fig.3).

Conclusion

DW and BOLD MRI can reflect changes of water diffusion and oxygen level in TIN kidney. Both methods can be used to study the TIN patients. Combined use of the two methods may aid in differentiating ATIN, CTIN from normal kidney. Medullary R2* significantly correlates with eGFR in TIN patients.

References:

- 1)Ma YC, Zuo L, Chen JH, et al. J Am Soc Nephrol 17,2006:2937-2944.
- 2)Hofmann L, Simon-Zoula S, Nowak A, et al. Kidney Int. 2006, 70:144-150.
- 3)Thoeny HC, Keyzer FD, Oyen RH, et al. Radiology, 2005, 235:911-917.