

The Effect of Maternal Smoking on Fetal Lung and Kidney Growth

D. Anblagan¹, C. Costigan², T. Paus², Z. Pausova², N. W. Jones³, G. Bugg³, N. R. Fenning⁴, and P. A. Gowland¹

¹Sir Peter Mansfield Magnetic Resonance Centre, University of Nottingham, Nottingham, Nottinghamshire, United Kingdom, ²Brain and Body Centre, University of Nottingham, United Kingdom, ³Queen's Medical Centre, University of Nottingham, United Kingdom, ⁴Division of Human Development, School of Clinical Sciences, University of Nottingham, United Kingdom

Introduction: There have been many concerns about the effects of smoking in pregnancy [1]. However, there is limited evidence on the differential effects of smoking on the growth of different fetal organs. The aim of this study is to investigate the effect of maternal smoking on the growth of the fetal lungs and kidneys.

Methods: Following ethics committee approval, 20 healthy pregnant women from Queen's Medical Centre Nottingham, 10 smokers and 10 non-smokers matched for age and education level were recruited and gave informed consent to participate in the study (only 5 non smokers have completed scanning at this stage). Data were collected on the women's smoking habits and smoke exposure. Pregnant women underwent two scans at 24-26 weeks of the fetus's gestational age (GA) and 34-36 weeks GA, using 1.5 T Philips Achieva MRI scanner with 5-element SENSE cardiac coil or 4-element SENSE torso coil. Women lay on their right side in the decubitus position to avoid vena cava compression; all these scans were conducted with a specific absorption rate of <2.0 W/kg. Three sequences were acquired to study the fetal growth: Half Fourier Single Shot Turbo Spin-Echo for the whole body (HASTEbody, 123 slices in 147 seconds, TE = 120ms and 0.78x0.78x6.00 mm³ voxels); high resolution HASTE to study the brain (HASTEbrain, 34 slices in 35.8seconds, TE = 120ms and 0.59x0.59x4.50 mm³ voxels); and Balanced Fast Field Echo for the abdominal organs (bFFE, 130 slices in 167 seconds, TR = 5.8ms, TE = 2.3ms, flip angle = 70° and 0.78x0.78x6.00 mm³ voxels). The pregnant women were allowed to breath freely during the scan and so three orthogonal non-breathheld blocks of images were acquired with both sequences to allow motion affects to be averaged out.

Data Analysis: The volume of the fetal kidneys and lungs were measured on at least two sets of images. These were generally HASTEbrain for lung and bFFE for kidney but HASTEbody was used instead if these sets of data were seriously affected by artefact (generally motion or sense artefacts). Data were analyzed using Analyze software (Mayo Biomedical Imaging Resource), and two approaches for segmenting organ volumes were compared: a semi automatic segmentation based on edge detection to reduce inter-observer errors and the Cavalieri method with 10x10 grid [2]. These approaches were used to measure the lung volumes in two subjects on five different occasions. It was found that the semi automatic approach produced better reproducibility (7%) than the Cavalieri method (12%). The errors in the Cavalieri method are expected to increase with smaller organs, so the automatic segmentation approach was used in the rest of the study. The two measurements on each organ were averaged together, but two measurements made on each organ varied by around 0-10% of its mean size across all fetuses. The final volume of kidneys (summed over left and right kidney) and lungs were divided by the fetus's estimated weight from ultrasound to correct the effects of smoking on total fetal growth from the effect on growth of particular fetal organs.

Results: Figure 1 shows fetal images highlighting the organs of interest. Figure 2 shows the variation in the volume of the fetal lung with gestational age for smokers and non smokers. Fractional lung volume is reduced in the smoking group at both gestational ages (one tailed t-test, p=0.007 at 24 weeks and p=0.02 at 36 weeks). Weight corrected (fractional) kidney volume is reduced in the smoking group at both gestational ages (one tailed t-test, p=0.006 at 24 weeks and p=0.01 at 36 weeks). Similar trends were observed in the raw lung and kidney volumes as well as estimated fetal weights but with greater levels of significance.

Discussion: Fetal lung and kidney volumes are reduced by maternal smoking during pregnancy and this effect persists even when the volume is corrected for estimate fetal weight. This study is ongoing and we are currently recruiting five non-smoking pregnant women. At this stage, the data suggest that the effect of smoking is more pronounced at early gestation than at late gestation, presumably because at early gestation fetal growth is most dominated by placental implantation whereas later it is also affected by other environmental factors. Future work will separate left and right kidneys and regions within kidney where possible. We will also measure brain volume in these fetuses.

Conclusions: Maternal smoking during pregnancy reduces growth of the fetal kidneys and lungs.

References: [1] L. Oaks. (2001), Smoking and Pregnancy: the politics of fetal protection, Rutgers University Press, United States of America.

[2] C.-O. LM, and N. Roberts. (1993), Unbiased volume estimation with coaxial sections: an application to the human bladder. Journal of microscopy 170 25-33.

Acknowledgments: This work is funded by the University of Nottingham.

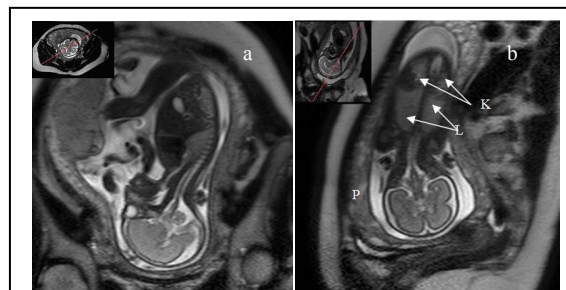


Figure 1: Magnetic Resonance Imaging (HASTE sequences): (a) Sagittal plane through fetus and (b) Coronal plane through fetus. K=kidney and L=lungs

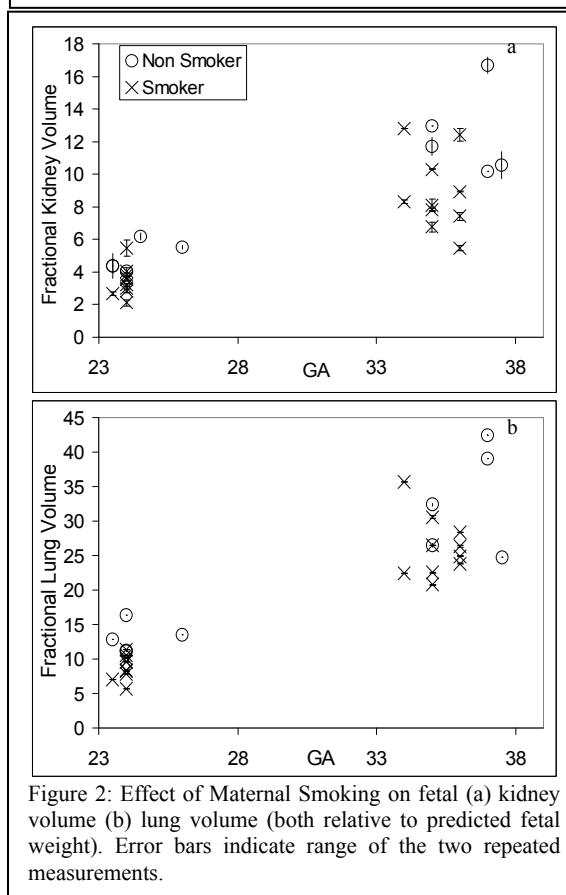


Figure 2: Effect of Maternal Smoking on fetal (a) kidney volume (b) lung volume (both relative to predicted fetal weight). Error bars indicate range of the two repeated measurements.