

THE IMPACT OF ABDOMINAL MRI OF PREGNANT WOMEN ON CLINICAL AND OBSTETRICAL MANAGEMENT

M. M. Amitai¹, M. stern¹, M. Hertz¹, Y. Itzhak¹, Y. Inbar¹, and S. Apter¹
¹Diagnostic Imaging, Sheba Medical Center, Ramat Gan, Israel, Israel

Background: US is usually the primary imaging modality for the investigation of abdominal pathology in pregnant women. CT exposes the patients to ionizing radiation and therefore is usually avoided. MRI having no known teratogenic effect on the fetus is increasingly used in evaluating the pregnant patient.

Purpose: To evaluate the impact of MRI of the abdomen and pelvis in pregnant women on clinical and obstetrical management.

Methods: Thirty one consecutive MRI studies of the abdomen of 29 pregnant patients, performed in the past four years (2005-to date), following an inconclusive US were included in the study. Patient age range was between 25-40years, (mean 31years) gestational age ranged between 14-37 weeks (mean 25.2 weeks).

All studies were performed on a 1.5T GE MR System. The MR protocol included: Ax, Cor, and Sag Fiesta TR/TE (4.3/1.9 ms), Ax and Cor 2D SSFSE T2W (1680-3200 /92.7 ms), Ax and Cor FSPGR FS BH TR/TE(150/1.3 ms).Manitol 5% (1000 ml) was orally administered 60 minutes prior to the examination to 11 patients. IV Injection of Gad (0.1 mmol /Kg) was added in 8 patients when necessary for diagnosis. MR findings were correlated with clinical course and surgical findings when available as well as obstetric outcome.

Results: The indications for MR studies included: gynecologic conditions (9), suspected Crohn disease(CD) or exacerbation(7),suspected appendicitis(6), cancer staging and follow up (5), postoperative complications(3)and suspected pheochromocytoma (1).

The gynecologic conditions included: three women with placenta accrete or previa, two with ovarian cysts, and one with a massive hemorrhagic myoma and one with a uterine scar tear. One patient had suspected ovarian vein thrombosis that was ruled out by the MRI study.

In the 7 studies for suspected CD, four were referred due to clinically suspected exacerbation. Colitis was found in two, phlegmon and fistula1 in two studies, no sign of active disease in one. One patient was suspected of having CD for the first time during pregnancy and in one patient the disease was ruled out.

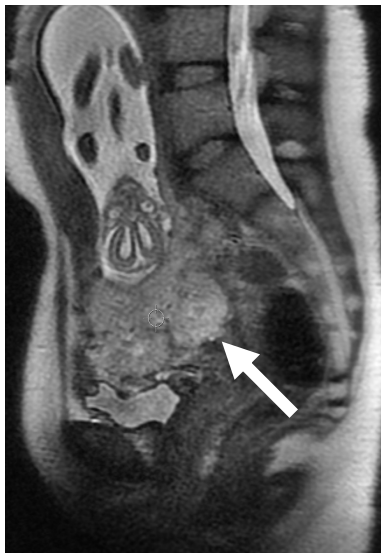In all six patients with suspected appendicitis the appendix was normal .Two of them had right painful hydronephrosis, and in one omental infarction was diagnosed .In all of the suspected appendicitis surgery was avoided.

In the group of patients with malignancy two had new onset of Hodgkin lymphoma that was diagnosed, staged and followed with MRI during pregnancy and one woman suspected recurrent lymphoma was ruled out. Cervix cancer was staged in two.

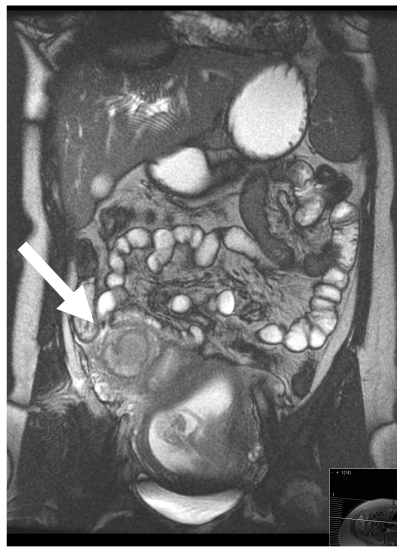
The post operative complications group included an abscess following appendectomy of a gangrenotic appendix, one patient with dehiscence of an anastomosis (after small bowel resection) and one with a perforated urachal cyst.

The obstetric outcome for 29 the patients included: 11 term deliveries, 14 preterm deliveries (before 36 weeks), and 2 lost pregnancy (uterine scar rupture at 22 weeks and one pregnancy interruption due to hypertension) .Nine babies were delivered by Cesarean sections. All babies were born healthy.

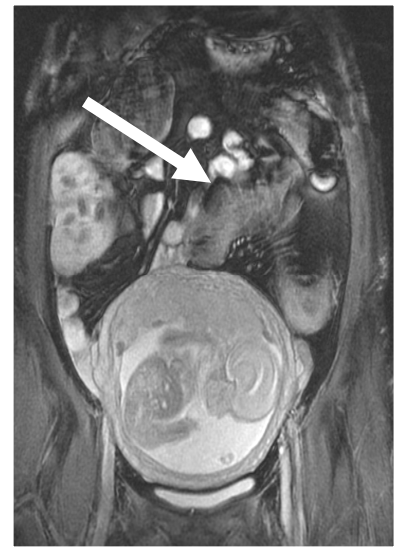Conclusions: MR imaging proved to be appropriate in the management of pregnant patients with various abdominal pathologies. Unnecessary surgery was avoided in patients with clinically suspected acute abdominal conditions. MRI added to US in the evaluation of obstetric conditions requiring urgent management prior to delivery. In pregnant women with malignancy it was the modality of choice for staging and follow up.In summary MR imaging can be considered as a first-line cross sectional imaging method in pregnancy as an adjunct to US as it does not expose mother and fetus to unnecessary ionizing radiation.



17 weeks of pregnancy
 Placenta previa and accreta
 (Sag FIESTA TR/TE 4.3/1.9ms)



14 weeks of pregnancy
 Abscess post appendectomy (Cor FIESTA)



19weeks of pregnancy
 Crohn colitis (Cor FIESTA)