

# Dynamic contrast-enhanced MRI in the liver at 3T with dual-input pharmacokinetic model analysis

A. B. Gill<sup>1</sup>, L. Mannelli<sup>1</sup>, P. Beddy<sup>1</sup>, R. T. Black<sup>1</sup>, I. Joubert<sup>1</sup>, A. N. Priest<sup>1</sup>, M. J. Graves<sup>1</sup>, and D. J. Lomas<sup>1</sup>  
<sup>1</sup>Dept of Radiology, University of Cambridge & Addenbrooke's Hospital, Cambridge, Cambridgeshire, United Kingdom

## Introduction

DCE-MRI has been widely used at 1.5T in a variety of organs and tissues. The aim of this study was to assess the feasibility of DCE-MRI in the liver at 3T, taking into account the challenges of 3T systems, and performed in such a way as to allow a dual-input pharmacokinetic analysis, separating the perfusion contributions from the hepatic artery and portal vein. To our knowledge, this is the first reported study of DCE-MRI of the liver at 3T.

## Methods

The study was approved by the local ethics review board and informed consent was obtained from 7 volunteers (6 male, 1 female). The volunteers fasted for 8 hours before the examination to ensure a basal portal vein flow. Examinations were performed on a 3.0T whole body MR scanner (Signa HDx, GEHC, Waukesha, WI) using an 8 channel cardiac array coil. The DCE series was collected using a saturation-prepared fast gradient echo sequence modified to add a saturation pulse train [1] for good preparation uniformity. Two independently oriented images were acquired per heartbeat, for 256 heartbeats [2]. Each image pair shared most parameters (matrix 128x128, ASSET factor 2, thickness 10mm, TR/TE/NEX = 3.4ms/1.1ms/1, flip 10°, BW 31.2 kHz, centric phase ordering) but had individually specified saturation times and prescription geometry. The first image of the pair sampled the two vascular input functions using an oblique orientation through the portal vein and aorta and employed a short saturation recovery time (TS=20 ms) to avoid clipping of the arterial input function. The second image was oriented sagittally through the liver and had a longer saturation recovery time (TS=200ms) targeting tissue gadolinium concentrations. A bolus injection of Gd-DPTA (Gadovist, Schering AG, Germany) was given after 20s of baseline imaging. Pre-contrast measurements of T<sub>1</sub> were made within a single breath-hold for each slice orientation, using a modified Look-Locker inversion recovery sequence (MOLLI) [3].

The data were analysed using customised software written in Matlab (The Mathworks, Natick, MA). Within the dynamic series and on the oblique slice set of images, regions of interest (ROI) were placed within the portal vein and aorta: physiological motion of the portal vein in the time series was tracked using a cross-correlation algorithm. A time course of signal intensity was extracted from these ROIs to give the arterial and portal venous input functions. A third ROI was placed on the sagittal images in an area of the liver parenchyma devoid of vasculature. Motion correction was performed by correlating the ROI position to the position of the diaphragm. The tissue enhancement curve was extracted from the time course of signal intensities. The following relationships were used to convert signal intensities to contrast agent concentrations (denoted by [Gd]):-

$$S = M_0(1 - \exp(-TS/T_1)) \text{ yielding } T_1, \text{ and } [Gd] = (1/r)(1/T_1 - 1/T_{10})$$

Here, 'r' is the relaxivity of the contrast agent (4.5 s<sup>-1</sup> mmol<sup>-1</sup> for Gadovist at 3T), 'T<sub>10</sub>' is the pre-contrast T<sub>1</sub> measurement and 'M<sub>0</sub>' is a normalisation factor. The latter was measured as the signal from a single independent acquisition of the DCE pulse sequence using a very long saturation recovery time (TS=10s). Blood concentrations were converted to plasma concentrations using an assumed hematocrit of 0.45/0.50 for female/male subjects respectively. A pre-contrast tissue T<sub>1</sub> value was obtained from the sagittal MOLLI images of the liver using the same ROI defined on the dynamic series. Pre-contrast T<sub>1</sub> values for blood were obtained from the oblique MOLLI images by placing ROIs in the inferior vena cava (IVC), and/or one of the heart chambers after assessing the image for artefacts. A mean of artefact-free values was used as the 'best blood T<sub>1</sub>' measurement. The concentration time courses ('C<sub>a</sub>', 'C<sub>p</sub>' and 'C<sub>L</sub>' for the hepatic artery, portal vein and liver parenchyma respectively) were fitted using a dual-input pharmacokinetic model [4] to yield five parameters, perfusion indices 'k<sub>1a</sub>', 'k<sub>1p</sub>' and 'k<sub>2</sub>' and the circulation time delays 'τ<sub>a</sub>' and 'τ<sub>p</sub>':-

$$\frac{dC_L}{dt} = k_{1a}C_a(t - \tau_a) + k_{1p}C_p(t - \tau_p) - k_2C_L$$

## Results

Examples of measured and fitted curves (from subject 'L01') are shown in Figure 1. The results are shown in Table 1. Total perfusion (P ml min<sup>-1</sup> 100ml<sup>-1</sup>) is calculated as 6000 x (k<sub>1a</sub> + k<sub>1p</sub>) and the arterial fraction (A %) as 100 x k<sub>1a</sub>/(k<sub>1a</sub> + k<sub>1p</sub>). The results for T<sub>1</sub> (blood 1638 ± 126 ms; liver 778 ± 66 ms) show good agreement with mean values from the literature (blood 1664 ± 14 ms [5]; liver 809 ± 71 ms [6]). Mean total perfusion is 69 ± 24 ml min<sup>-1</sup> 100ml<sup>-1</sup>, which is in line with that reported in studies by other groups at 1.5T (eg 138 ± 69 ml min<sup>-1</sup> 100g<sup>-1</sup> [7]), as is mean arterial fraction 16 ± 7 % (cf 7.5 ± 7.9 % [7]). The mean time delay parameters were τ<sub>a</sub> = 8.1 ± 2.8 s and τ<sub>p</sub> = 7.5 ± 1.6 s.

## Conclusion

This work demonstrates the feasibility of DCE-MRI and dual-input pharmacokinetic modelling in the liver at 3T. This work is the preliminary stage for patient studies evaluating DCE-MRI in both chronic diffuse liver disease and hepatocellular carcinoma.

## References

- [1] Kim D, et al Magn Reson Med 2008;59:209-215
- [2] Black RT, et al Proc ISMRM 3562 (2007)
- [3] Messroghli DR, et al. Magn Reson Med 2004;52:141-146
- [4] Materne R, et al Magn Reson Med 2002;47:135-142
- [5] Lu H, et al Magn Reson Med 2004;52:679-682
- [6] de Bazelaire C, et al Radiology 2004;230:652-659
- [7] Hagiwara M, et al Radiology 2008;246:926-934

## Acknowledgements

Addenbrookes Charitable Trust, NIHR Cambridge Biomedical Research Centre, GE Healthcare Technologies

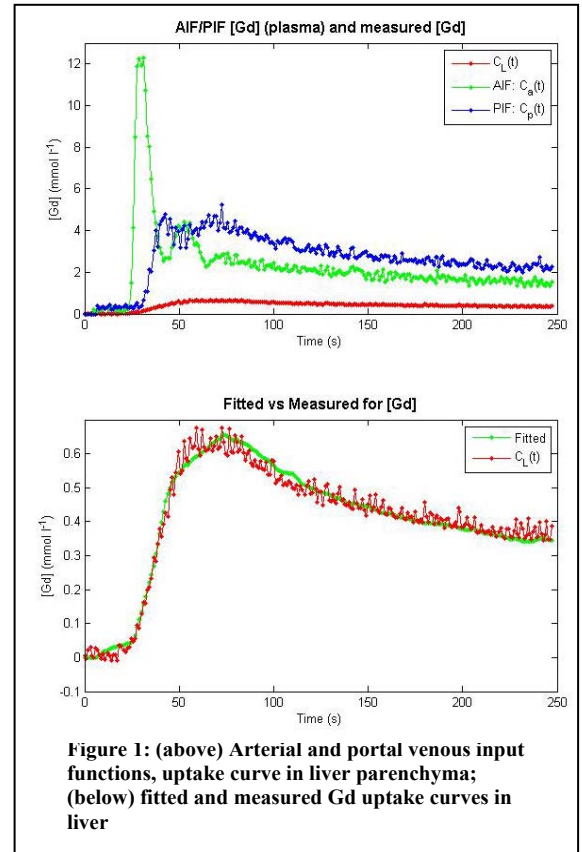


Figure 1: (above) Arterial and portal venous input functions, uptake curve in liver parenchyma; (below) fitted and measured Gd uptake curves in liver

Table 1: Total perfusion (P) and arterial fraction (A%)				
Subject	Liver T <sub>1</sub> (ms)	Blood T <sub>1</sub> (ms)	P (ml min <sup>-1</sup> 100ml <sup>-1</sup> )	A (%)
L01	762	1841	103.6	13.5
L02	815	1634	34.6	26.3
L03	745	1533	57.0	11.3
L04	748	1746	56.3	8.9
L05	909	1652	76.5	26.7
L06	708	1594	93.4	10.5
L07	761	1468	61.9	13.5
Mean	778 ± 66	1638 ± 126	69.0 ± 23.8	15.8 ± 7.4