

Flip angle Optimization with Hepatobiliary Contrast Agents at 3T

S. L. D'Souza¹, A. P. Frydrychowicz¹, K. K. Vigen¹, S. K. Nagle¹, and S. B. Reeder²

¹Radiology, University of Wisconsin, Madison, WI, United States, ²Radiology, Medical Physics, Biomedical Engineering, and Medicine, University of Wisconsin, Madison, WI, United States

INTRODUCTION: To date, two FDA-approved Gadolinium-based contrast agents Gd-EOB-DTPA (Gadoxetate, Eovist, Bayer Pharmaceuticals, Wayne, NJ), and Gd-BOPTA (Gadobenate, Bracco Diagnostics, Princeton, NJ) are available for hepatobiliary imaging. The pharmacokinetics of these agents are different, with approximately 4-5% hepatic uptake with Gd-BOPTA at 1-2 hours¹, and 50% uptake of Gd-EOB-DTPA at approximately 20 minutes². T₁ weighted 3D spoiled gradient echo (SPGR) imaging for dynamic contrast enhanced imaging typically uses 12-15° flip angles for observing enhancement in liver lesion and normal liver parenchyma. Recent work by Nagle et al³ at 1.5T, however, demonstrated that higher flip angles such as 30-40° provide improved contrast of liver parenchyma and bile ducts for delayed hepatobiliary imaging with Gd-EOB-DTPA. The increasing use of abdominal imaging at 3T, however, necessitates optimization of T₁ weighted imaging at 3T, as well as evaluation of Gd-BOPTA. Therefore, it was the aim of this study to analyze and directly compare the optimal flip angle for high-resolution hepatobiliary imaging at 3T using Gd-EOB-DTPA and Gd-BOPTA through a cross-over study in normal volunteers.

MATERIALS AND METHODS: To date, 6 healthy volunteers (25.8±4.9years, 66±16kg, 169±12cm, 4 female) have been recruited and scanned twice with a washout interval of 2 to 3 weeks. Volunteers were scheduled to receive each contrast agent in a randomized order, followed by cross-over to the other agent on the second exam. Written informed consent was acquired from each individual after IRB-approval of the study.

Scans were performed on a 3T clinical scanner (Discovery MR 750, GE Healthcare, Waukesha, WI) using a 32-channel phased array body coil (NeoCoil, Pewaukee, WI). A T₁ weighted 3D spoiled gradient echo (SPGR) acquisition with intermittent spectrally-selective partial inversion to suppress fat was acquired with a fixed TR for the flip angles 15, 20, 25, 30, 40, and 45°. Additional parameters included: TR/TE=5.4/2.1ms, BW=±62.5kHz, FOV=40cm, matrix=288x224, slices=100 slice thickness=2.0mm, for a near isotropic true spatial resolution of 1.4x1.8x2.0mm³ (interpolated to 0.8x0.8x1.0mm³). The acquisition was accelerated using an autocalibrated 2D parallel imaging method known as ARC⁴, with a nominal acceleration of 2 in both phase and slice encoding directions and a 24 x 24 central fully calibrated region, for a net acceleration of 3.56, and a total breath-hold time of approximately 22s. High-resolution imaging was necessary for this study in order to measure signal intensities in small bile ducts.

Image acquisition was performed 25-35min after Gd-EOB-DTPA injection and 75-85min after Gd-BOPTA administration, respectively. Dosing was 0.1mmol/kg for Gd-BOPTA and 0.05mmol/kg for Gd-EOB-DTPA, which are the doses used clinically at our institution. The dosing and the delay times for hepatobiliary phase imaging are based on our clinical practice and those published in the literature^{1,2}.

Image analysis was performed placing regions of interest (ROI) in liver tissue free of large vessels, muscle, hepatic vein, portal vein, and the common bile duct. Muscle was measured as a reference tissue outside the liver. Due to the use of parallel imaging, absolute SI values were used rather than SNR or CNR that would have been corrupted by spatially varying noise distribution⁵.

RESULTS: Excellent image quality was obtained in all volunteers in all studies. Example images of delayed hepatobiliary images acquired with Gd-EOB-DTPA and Gd-BOPTA from the same volunteer are shown in figure 1. In addition, pooled signal intensity curves from all 6 volunteers are shown for both Gd-EOB-DTPA acquired at 25-35 minutes, and for Gd-BOPTA acquired at 75-85 minutes. Both contrast agents show similar behavior as the flip angle is varied. With both agents, the background muscle and vessels show progressive suppression at higher flip angles, while the liver and bile ducts show maximum signal intensities at higher flip angles with Gd-EOB-DTPA, compared to Gd-BOPTA.

The signal contrast relative to the liver parenchyma at each flip angle is also plotted in Figure 2 for both Gd-BOPTA and Gd-EOB-DTPA. These plots show that for hepatobiliary imaging with Gd-BOPTA at 75-85 minutes, a 20° flip angle maximizes contrast between the liver and the vessels, while a 25° flip angle maximizes the contrast between liver and bile ducts. For Gd-EOB-DTPA imaging at 25-30 minutes, a 25-30° flip angle maximizes contrast between liver and blood vessels, and a 40-45° flip angle maximizes contrast between liver and enhancing bile.

DISCUSSION & CONCLUSION: This study underscores the need to adapt flip angle for optimal visualization of the liver and bile ducts. Differences in the optimum flip angles for Gd-BOPTA and Gd-EOB-DTPA are due to a combination of differences in relaxivity^{6,7}, dose (0.1mmol/kg vs 0.05mmol/kg), and pharmacokinetics. Future work will explore these differences and their subsequent effects on image quality.

REFERENCES: [1] Spinazzi et al. *Acad Radiol* 1999; [2] Hamm et al. *Radiology* 1995; [3] Nagle *ISMRM* 2009 pg 2076; [4] Brau et al. *Magn Reson Med*. 2008; [5] Pruessmann et al. *Magn Reson Med*. 1999; [6] Pintaske et al. *Invest Radiol*. 2006; [7] Weinmann et al. *Magn Reson Med* 1991.

ACKNOWLEDGEMENTS: We wish to thank Bayer and Bracco for their support.

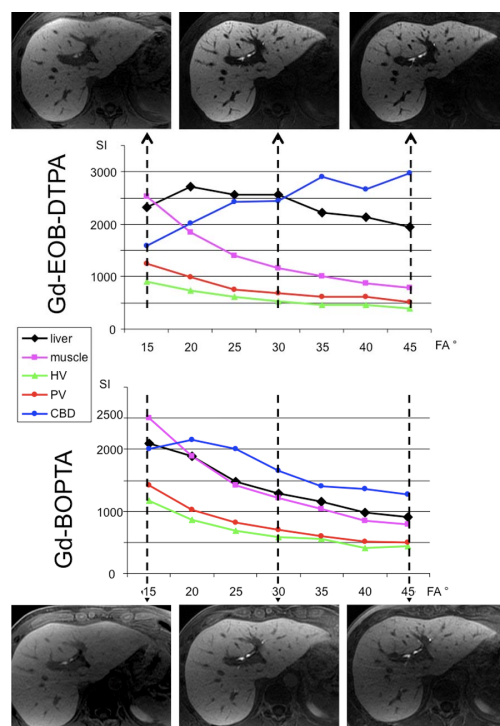


Figure 1 - Intersubject comparison of signal intensity (SI) values for different tissues over a range of flip angles for both Gd-EOB-DTPA (top) and Gd-BOPTA (bottom). (HV =hepatic vein; PV=portal vein; CBD=common bile duct)

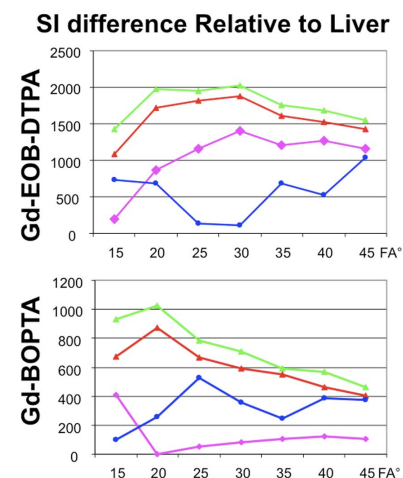


Figure 2: signal differences relative to liver for Gd-EOB-DTPA (top) and Gd-BOPTA (bottom), pooled for all patients. For Gd-BOPTA, a 30-35° flip is best for liver-vessel CNR and 40-45° flip for liver-bile duct CNR. For Gd-EOB-DTPA, a 20° flip is best for liver-vessel CNR and 25° for liver-bile duct CNR.