

EFFECT OF INTRAVENOUS GADOLINIUM ON ESTIMATION OF LIVER STIFFNESS WITH MR ELASTOGRAPHY

S. K. Venkatesh¹, L. L. Teo¹, B. W. Ang¹, and R. L. Ehman²

¹Diagnostic Imaging, National University Health System, Singapore, Singapore, Singapore, ²Radiology, Mayo Clinic, Rochester, MN, United States

Purpose: To evaluate the effect of intravenous gadolinium on estimation of liver stiffness with MR Elastography (MRE) for detection of liver fibrosis.

Methods: Liver MRI and MRE were performed in 32 subjects. The indications for liver MRE were suspected fibrosis/cirrhosis (n=24) and liver tumour (n=8). All MRI studies were performed on a single 1.5 Tesla clinical MR scanner (GE, Milwaukee, USA). The MRE was performed before (pre-Gd MRE) and at the end of standard Liver MRI protocol immediately after the 5 minute delayed phase (post-Gd MRE) in the same session. MRE was performed with modified phase-contrast gradient-echo sequences with TR/TE=100/27 ms FOV=30-46cm, 4 x 10 mm slices, gap 5 mm). The sequence automatically generated stiffness maps (elastograms). Mean stiffness values of the liver parenchyma were measured by an experienced reader and by placing at least three large circular regions of interest in each of the four slices. A mean liver stiffness value in kilopascals (kPa) was calculated by averaging the values from all the four slices. Liver biopsy revealed fibrosis in 25 patients and there was no fibrosis in seven patients. The pre-Gd MRE and post Gd MRE mean liver stiffness values were compared for any significant differences. Receiver operating curve (ROC) analysis was performed and area under curve (AUC) was measured for comparing accuracies for detection of liver fibrosis.

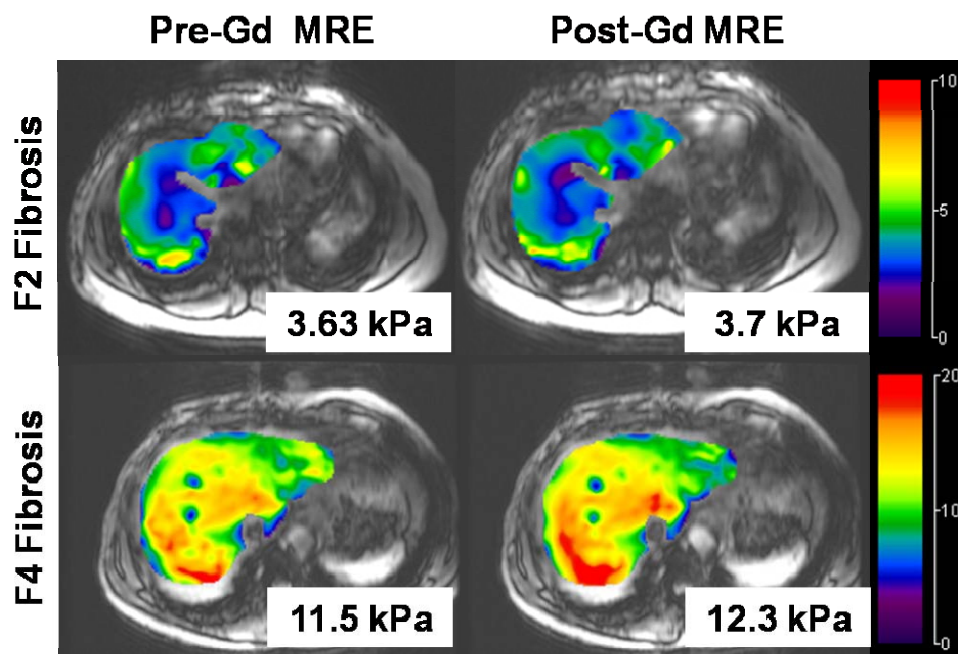


Figure 1. Cases of liver fibrosis with MRE performed before and after IV gadolinium. Top row is an example of chronic hepatitis B with F2 stage fibrosis and the bottom row is an example of cirrhotic (F4 stage) The MRE values are similar in both pre and post Gd sequences.

Results: There were no significant differences in the mean stiffness values measured on pre-gadolinium and post gadolinium enhanced sequences (fig.1). There was an excellent correlation between the mean stiffness values measured on pre-Gd MRE and post-Gd MRE ($R^2=0.98$, $p<0.001$). ROC analysis showed similar AUC/sensitivity /specificity for both pre-Gd MRE and post-Gd MRE (99.5/ 94.7%/ 100% (> 2.83 kPa), $p<0.01$ and 99.9/ 95%/100% (> 2.91 kPa), $p<0.01$ respectively for detection of liver fibrosis.

Conclusion: Intravenous gadolinium had no significant influence on estimation of liver stiffness values with MRE and does not affect diagnostic performance of liver MRE for fibrosis detection