

Orthotopic liver transplantation: MRI based measurement of donor graft steatosis, graft performance and outcome.

D. J. LOMAS¹, R. T. BLACK¹, A. J. PATTERSON¹, K. G. HOLLINGSWORTH¹, S. DAVIES², G. J. ALEXANDER³, M. E. ALLISON³, N. V. JAMIESON⁴, A. E. GIMSON³, R. K. PRASEEDOM⁴, and C. J. WATSON⁴

¹Radiology, University of Cambridge & Addenbrooke's Hospital, Cambridge, Cambridgeshire, United Kingdom, ²Pathology, University of Cambridge & Addenbrooke's Hospital, Cambridge, Cambridgeshire, United Kingdom, ³Hepatology, University of Cambridge & Addenbrooke's Hospital, Cambridge, Cambridgeshire, United Kingdom, ⁴Surgery, University of Cambridge & Addenbrooke's Hospital, Cambridge, Cambridgeshire, United Kingdom

Introduction

In recent years the indications for human liver transplantation have increased but the supply of cadaveric donor organs has not and even with the use of live donors a substantial number of potential recipients die on the waiting list. As a result there is particular interest in maximising the use of donor organs and several features including steatosis have been identified as negative factors associated with worse outcomes [1,2]. Owing to the small time window between retrieval and transplantation donor graft evaluation is based primarily on visual assessment by the implanting surgeon. MR based methods for rapid assessment of donor cadaveric graft steatosis have been previously developed [3-6]. The aim of this work is to investigate in cohort of liver transplant patients firstly whether a rapid MR evaluation of graft steatosis correlates with surgical and subsequent pathology evaluation and secondly if there is any correlation with early graft performance and longer term graft survival.

Methods

Ethical Committee approval and informed consent from potential liver transplant recipients on our institutional waiting list was obtained. Following receipt of a donor liver graft, surgical benchwork was performed and the graft replaced in a sterile bag containing preservation solution and surrounded by crushed ice in a plastic insulated transport container. During the period of recipient anaesthetic and surgical preparation the graft was transported to the MRI suite in its metal free insulated transport box and examined (Fig1). *MR protocol:* Exams were performed on a 1.5T whole body MRI (Excite, GEHT, Milwaukee). Coronal I/O phase gradient echo scans were acquired during 20 second acquisitions (matrix 256 x 128, 8 sections, section:10mm, gap:1.5mm, TR/TE/NEX = 180/2.2 (out of phase), 4.4 (in phase)/1, at both flip angles 20° and 70°). A T2* map of the liver was obtained using a location-matched, multi-slice, multi-echo gradient sequence (TR = 120ms, 8 equally spaced echoes, TE1 = 2.2 ms, TE2 = 4.4 ms, etc) and the first 4 even echoes used for T2* relaxation correction[5]. Using a matlab based purpose designed tool 3 circular ROIs were placed over the liver on each of 4 sections (Fig. 2) avoiding large vessels and matching the locations across the data sets the mean percentage fat and s.d. were calculated [5,6]. Peri-transplantation parameters included: Surgical visual assessment of hepatic steatosis and subsequent histopathological steatosis assessment (none/mild/moderate/severe) from time-zero biopsy. Early graft performance was evaluated using the peak values of standard clinical serum parameters (total bilirubin, ALT & prothrombin time) during the first week following transplantation. Graft survival was recorded at 3 & 12 months.

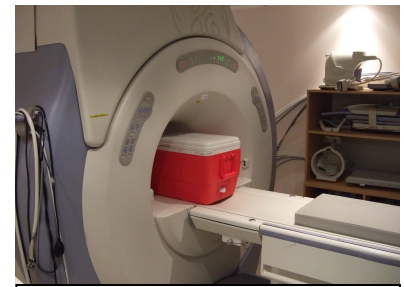


Figure 1: Donor graft within insulated transport box being examined on whole body 1.5T MR system.

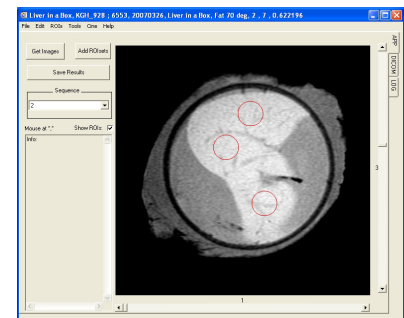


Figure 2: Typical ROI placement on one section of graft in the purpose designed analysis tool.

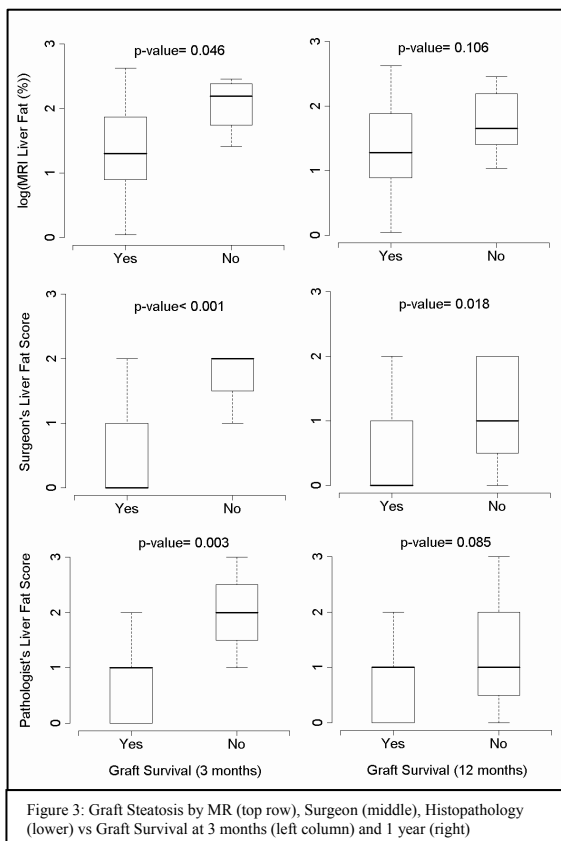


Figure 3: Graft Steatosis by MR (top row), Surgeon (middle), Histopathology (lower) vs Graft Survival at 3 months (left column) and 1 year (right)

Results

During the period August 2005 to February 2008 forty-nine grafts were examined out of a total of 164 transplants performed. Of the remaining 115 cases 45 were unable or unwilling to consent, in 6 there was insufficient time to undertake the MRI study and in the remainder either MRI system time or personnel to perform the study were unavailable. There were 32 males & 17 female recipients with an age range of 32 to 70 years. The primary indication for transplantation was malignancy in 9 cases and liver synthetic functional failure in the remainder. Four grafts failed by 3 months and 7 by 12 months. MR estimation of graft steatosis ranged from 0.04 to 12.77% and this was significantly correlated with surgical assessment (p=0.044) and pathology estimation (p=0.01). There was no significant correlation with any of the first week serum markers. MR estimated hepatic steatosis was significantly increased in 3 month graft failures (p=0.022) but not significant at 12 months (p=0.095). Subsequent histologically scored graft steatosis gave similar results with significantly increased steatosis in 3 months failures (p=0.003) but not for 12 month failures (p=0.85). The surgical visual assessment of increased steatosis was the best predictor of graft failure at both 3 months (p<0.001) and 12 months (p=0.018) see Figure 3.

Conclusions

Although a relatively small cohort the results of this study demonstrate that MRI quantification of donor liver graft steatosis obtained during the liver transplantation process is significantly correlated with the corresponding pathology and surgical visual assessment. The MR based and pathology estimates both demonstrated a significant increase in steatosis in graft failure cases at 3 months but not at 12 months. The surgical visual assessment proved the best predictor of both short and long term graft survival. We speculate that this difference may be due to adverse factors other than fat that are difficult to separate out (such as apparent ischaemia) that may influence the appearance of the graft for the surgical visual assessment. Further analysis will be performed including the evaluation and impact of the "donor risk index" on these results. Overall the results indicate that MR based non-invasive evaluation of donor graft steatosis pre-implantation provides similar results to subsequent histopathology assessment regarding graft outcome and is a potential future tool for further research into the importance of graft steatosis in the selection and outcome of graft recipients.

Acknowledgements:

Addenbrookes Charitable Trust, NIHR: Cambridge Biomedical Research Centre, Andrew Patterson, Jane Smith, Jason Polzin (GE Healthcare), Celia Chan, theatre staff, transplant co-ordinators & surgical team.

References :

- [1] Bussutil *et al.*, *Ann Surg.* **241**(6):905-16 (2005)
- [2] Zamboni *et al.*, *Clin Transplant.* **15**(1):53-7 (2001)
- [3] Hollingsworth *et al.*, *Proc. Intl. Soc. MRM* **14**, 2297 (2006)
- [4] Hollingsworth *et al.*, *Proc. Intl. Soc. MRM.* **14**, 2200 (2006)
- [5] Fishbein *et al.*, *Magn. Reson. Imag.* **15**, 287 (1997)
- [6] Hussein *et al.*, *Radiology* **237**,1048 (2005)