

Automated T2* Estimation with Complex-Signal Based Weighted Least Squares Exponential Fitting

S. S. Vasawala¹, H. Yu², A. Shimakawa², M. Jeng³, and J. H. Brittain⁴

¹Department of Radiology, Stanford University, Stanford, CA, United States, ²Applied Science Laboratory, GE Healthcare, Menlo Park, CA, United States, ³Department of Pediatrics, Division of Hematology/Oncology, Stanford University, Stanford, CA, United States, ⁴Applied Science Laboratory, GE Healthcare, Madison, WI, United States

Introduction Patients who receive chronic red blood cell transfusion therapy (i.e. patients with thalassemia, myelodysplastic syndromes, sickle cell and Diamond-Blackfan anemia) are at risk for iron overload if not receiving appropriate iron chelation. The range of therapeutic options for chelation has increased recently with the availability of oral iron chelation, which typically starts during childhood. Quantification of iron deposition in various organs for therapeutic decision-making is vital, and recently has become possible via T2* mapping. This technique may be valuable for iron quantification of the heart and liver to guide chelation therapy. However, the use of MRI for this purpose is hampered by several issues: 1) post-processing to calculate T2* in most clinical settings is not automated and requires skilled personnel, 2) pediatric patients often have severe iron overload, and hence all but the shortest echoes contain very little signal and are dominated by noise, making accurate quantification challenging, and 3) the presence of hepatic steatosis can potentially confound T2* measurements.

To address these issues, we aim to evaluate clinically a method of automated T2* mapping with fat-water decomposition and a weighted least squares algorithm in pediatric patients with suspected hepatic iron deposition and to compare it with a conventional T2* mapping method.

Methods Pediatric patients referred for MRI to evaluate iron overload from June 2008 to October 2009 were recruited with IRB approval and informed consent/assent. All studies were performed on a GE 1.5T HDx scanner (GE Healthcare, Waukesha, WI). Patients' livers were scanned with a 3D multiecho gradient echo sequence (8 echoes, TE1 ~ 0.9 ms, TE increment of 1.5 to 1.6 ms, 160 x 128 matrix, 24 slices, parallel imaging outer acceleration factor of 2, 19 second breath hold scan). Images were reconstructed with an online automated algorithm, referred to as "T2*-IDEAL" [1], that performed fat-water separation as well as T2* fitting of complex data using a nonlinear weighted least squares technique, resulting in water, fat and T2* maps. Additionally, patients were scanned with a cardiac gated 2D multiecho gradient echo sequence in the cardiac short axis that included the liver in the field of view (6 to 16 equally spaced echoes, first TE approximately 1.7 ms and second TE approximately 3.9 ms); T2* fitting of the liver was then performed from a region of interest in the liver using a conventional exponential fit without background noise subtraction, referred to as the "multi-echo exponential" technique [2]. The resulting pair of T2* measurements in each patient were then compared.

Results Twenty-three patients ages 5 to 17 years with various underlying diagnoses were recruited. Estimated T2* ranged from 1.2 ms to 42 ms using the automated T2*-IDEAL method. For six patients, attempted simple exponential fitting of magnitude data failed to yield a confident T2* estimate; each of these patients had an estimated T2* of 1.2 to 1.9 ms by the automated T2*-IDEAL technique. Results from two patients with moderate and severe iron overload are shown in Figure 1. With the remaining 16 patients, good correlation was obtained between the methods with R² of 0.97, as shown in Figure 2a. The mean of the T2* differences from the two methods is -0.65ms and the 95% confidence interval (CI) of the differences is [-4.4, 3.1], shown in the Bland-Altman plot (Figure 2b). It is noted that the T2* is over-estimated with the multi-echo exponential technique for patients with short T2*, demonstrated in Figure 3, which may explain the non-zero intercept of -1.9 ms seen in Figure 2a. In addition, two patients had significant hepatic steatosis, though estimated T2* in each case differed little between the automated and conventional methods (case 1: fat fraction 37% with conventional versus automated T2* of 12 and 10 ms, case 2: fat fraction 28% with conventional versus automated T2* of 13 versus 11 ms). This is due to the fact that the shortened T2* generates an exponential decay that dominates over the water-fat oscillation. Therefore, multi-echo exponential fitting may still be accurate despite its ignorance of the fat presence.

Conclusion: Automated T2* fitting of complex data with fat-water decomposition and a weighted-least squares algorithm is feasible and correlates well with exponential fitting in a pediatric population with iron overload. At short T2*, a simple exponential fit likely overestimates T2*.

References [1]. Yu et al, JMRI 2007;26(4):1153-1161. [2]. Stanley et al, ISMRM 2004: 892.

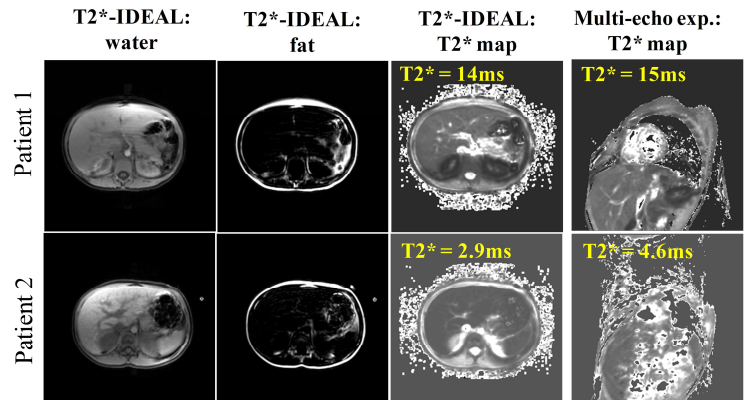


Figure 1: representative results from two patients. Water and fat images from the T2*-IDEAL technique are shown in addition to the T2* maps from the two techniques.

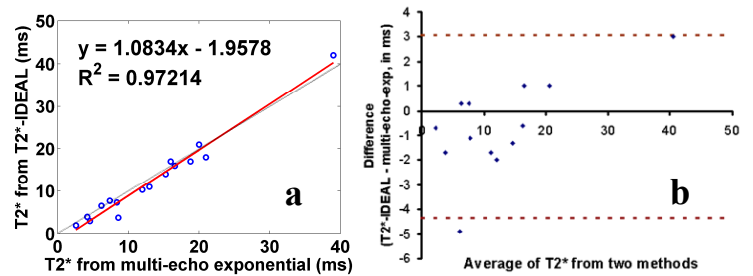


Figure 2: T2* values measured from the two techniques shown by the correlation plot (a) and the Bland-Altman plot (b).

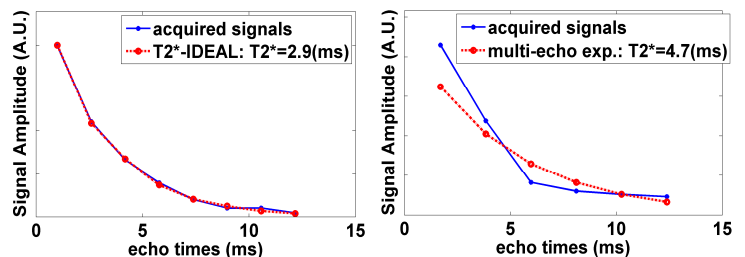


Figure 3: Fitting of representative liver voxels from the two techniques in Patient 2 of Fig. 1. T2*-IDEAL, based on complex data and weighted least squares, accurately captures the T2* decay, whereas the multi-echo exponential fitting demonstrates over-estimation of the T2*.