

## Detection and characterization of physiologic lung changes after placement of bronchial valves: A case study.

J. Mata<sup>1</sup>, T. Altes<sup>1</sup>, S. Springmeyer<sup>2</sup>, J. Truwit<sup>1</sup>, E. de Lange<sup>1</sup>, P. Sylvester<sup>1</sup>, and J. Mugler III<sup>1</sup>

<sup>1</sup>University of Virginia, Charlottesville, Virginia, United States, <sup>2</sup>Spiration Inc, Redmond, Washington, United States

**Introduction:** The IBV Valve (Spiration, Inc, Redmond, Wash), which is currently undergoing Phase III clinical trials in the US, provides a minimally invasive treatment approach for patients with severe emphysema. This small one-way valve can be placed during a single bronchoscopic procedure in selected bronchi, helping redirect airflow to less affected regions of the lung while still permitting expiratory flow of mucus and air from areas distal to the valve (1). Currently, multiple valves are placed in bronchi feeding the upper lobes of the lungs in patients with upper-lobe predominant emphysema (2). Although this region is typically the first area to be affected, in some cases less affected lung may be obstructed. The development of a clinical imaging modality that can generate high-resolution, three-dimensional functional maps of the lung could provide a more targeted approach to valve placement.

**Purpose:** To determine whether hyperpolarized helium-3 (HHe) ventilation and diffusion MR imaging can detect changes in lung function and microstructure resulting from bronchial valve placement.

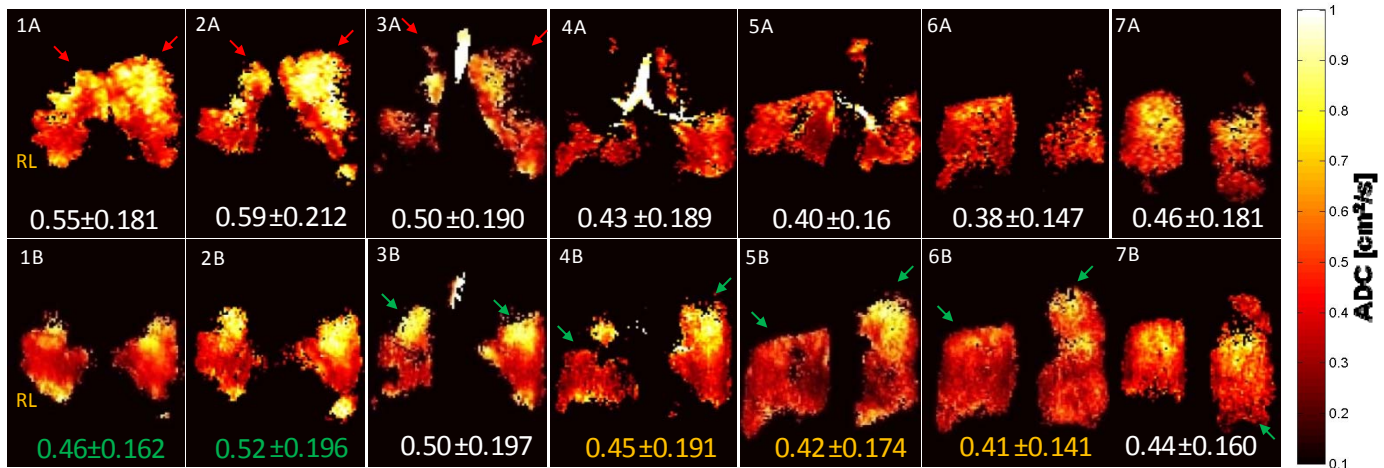
**Methods:** One patient diagnosed with emphysema had 9 IBV placed in bronchi leading to the lung upper lobes. Imaging was performed before and 6-months after IBV placement. Coronal HHe ventilation MR images, acquired during a 10s breath-hold, were used to assess volume changes in the ventilated portions of the lung. Coronal HHe diffusion MR images, acquired with b-value pairs of 0 and 1.6 s/cm<sup>2</sup> during a second 10s breath-hold, were used to compute apparent diffusion coefficient (ADC) values. Pulmonary function tests were also performed for comparison.

**Results:** Anterior and medial regions of the upper lobes did not appear ventilated post-IBV placement (Figs. 1-3, red arrows); however, medial and posterior regions of the lower lobe, particularly in the right lung, showed an increase in HHe ventilation (Figs. 3-7, green arrows). A shift of the fissure in the right lung towards the head produced a mean increase of 27% in the ventilated volume for medial HHe slices (Figs. 5, 6), and an estimated 20% increase in total ventilated lung volume ADC maps of the anterior lung showed a 9% decrease in mean ADC post-intervention, largely due to the absence of signal from the emphysematous upper lobes. ADC maps of the medial and posterior lung showed a 6% increase in mean ADC post-intervention due to ventilation of regions that were not ventilated before intervention.

**Conclusion:** HHe MR imaging appears to provide a safe, non-invasive method for measuring functional and structural changes in the lungs after IBV placement.

**References:** 1) Coxson H, et al., Eur Respir J 2008; 32:1443-1450; 2) Springmeyer S, et al., Thorac Surg Clin. 2009;19(2):247-253.

**Acknowledgements:** Supported by NIH R01 HL079077.



Figures - HHe ADC maps for seven contiguous coronal slices covering the entire lung volume acquired at baseline (top row) and 6-months after (bottom row) placement of 9 IBVs in the upper lobe bronchi. ADC values (Mean ± SD) are given for each slice. Relative decreases and increases in the ADC values are highlighted by green and yellow text, respectively. Red arrows emphasize areas of high ADC values, presumed to be severely emphysematous tissue, targeted by the placement of IBVs (1A-3A). Green arrows emphasize areas where ventilation improved post-IBV placement (3B-7B). Note: the presence of non-zero values in the ADC maps indicates the presence of ventilation for the associated region.