

Influence of contrast arrival time and temporal resolution in diagnosis of breast cancer with DCE-MRI

H. Laue¹, A. Hennemuth¹, V. Diehl^{1,2}, M. T. Harz¹, H. K. Hahn¹, and H-O. Peitgen¹

¹Fraunhofer MEVIS, Bremen, Germany, ²Institute of Magnetic Resonance Imaging, Central Hospital St.-Juergen-Strasse, Bremen, Bremen, Germany

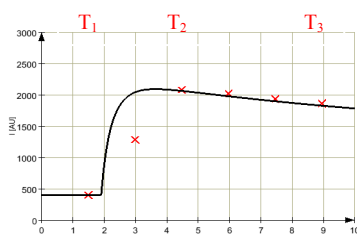


Fig. 1: Model (black line) and resampled curve (red crosses).

Moreover, there is a broad range of protocols, sequences and contrast agents used for breast MRI. These variations pose a large obstacle in the comparison of Breast MRI data from different centers. Moreover, inadequate measurement settings might result in decreasing diagnostic accuracy. To some extent, simulations can help identify the most important parameters influencing the result of the diagnosis. In this work, some experiment related to contrast arrival time (CAT) which is depended on the cardiovascular situations in the patient. Moreover, the variations from low temporal resolution were investigated.

Methods and Materials: The simulations were based on the Tofts model [3]. Simulated was a GE sequence (TE=2 ms, TR=4.3, $\alpha=10^\circ$, $S_0=400$). The plasma concentration was set as proposed in [3]. A dose of 0.1mmole/kg Gd-DTPA was assumed. The model was used to calculate 1000 time points for a period of 10 min. The parameter K^{trans} was varied from 0.1 to 1.3 min^{-1} in steps of 0.012 min^{-1} for 3 fixed v_1 (20, 40, 60%). v_1 was varied from 10 to 80% in steps of 0.7% for 4 K^{trans} (0.3, 0.6, 0.7, 1.0 min^{-1}). Low temporal resolution was simulated by averaging over the new interval and an offset was simulated by extending the pre-contrast phase. A curve shape estimation algorithm based on [4] was applied to the new curves (see Fig. 1). The enhancement at 2 min (T_2) is compared to the one at 6 min (T_3) after the pre-contrast measurement (T_1). A late enhancement >10% is classified as wash-in, a decreased by 10% as wash-

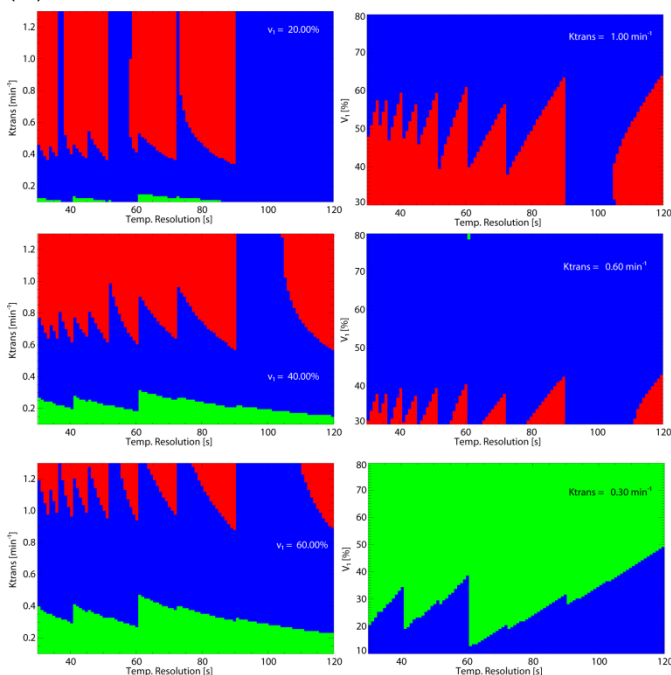


Fig. 3: Dependency of the curve shape estimates on the temporal resolution. Left: Comparison for K^{trans} . The discrete sampling results in a tooth saw pattern for the different curve shape classifications. This effect is more prominent for the change from plateau to wash-out-curves. Right: Comparison with v_1 . This comparison shows the same effect.

Introduction: The consensus on diagnosis of breast cancer with DCE-MRI is the use of sequences with high spatial and low temporal resolution, because of the inhomogeneous distribution of pharmacokinetic properties in the tumor and the requirement to detect small lesions [1,2]. The diagnostic in breast MRI today is therefore based on simple curve shapes rather than pharmacokinetic modelling.

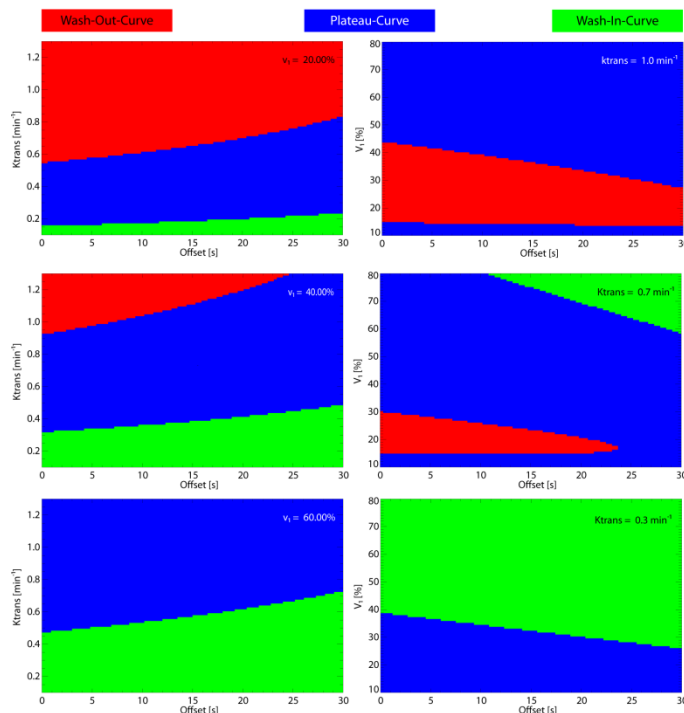


Fig. 2: Dependence of the curve shape model on the influence of the CAT. Left: Comparison with K^{trans} for three different v_1 : An increasing offset leads to an underestimation of potentially malignancies. Right: Comparison with v_1 for three different K^{trans} : here, an increasing offset also leads to an underestimation of curve shape.

out curve. The remaining cases are classified as plateau. T_2 and T_3 are set to the measurements closest to 2 or 6 min, respectively. All simulations were conducted for fixed temporal resolutions. Two types of experiments were carried out: First, a temporal offset of 0-30 s [5] was added to the curves and the resulting classification was determined. Second, the temporal resolution was varied ranging from 30 to 120 s, which is about the range of measurements currently used in breast MRI, and the resulting classification was also determined. The results were displayed as color encoded diagrams (see Fig 1 and 2).

Results: Fig. 2 shows the results for the experiments on the CAT time. For all simulations of fixed pharmacokinetic parameters, the outcome of the shape model is shifted to less malignant curves. Nevertheless, the regular shape of the areas indicates that a correction for CAT is applicable. Fig. 3 shows the results for the experiments on temporal resolution. Here, a tooth saw pattern is visible, indicating that higher temporal resolution can perform worse than slightly lower resolutions. Further pharmacokinetic modelling might allow identifying the optimal temporal resolution.

Discussion: These initial experiments show a strong dependency on temporal offset as well as temporal resolution for the curve shape based methods in breast MRI. Nonetheless, the inhomogeneous distribution of pharmacokinetic parameters in breast tumours and the requirement to identify small lesions still requires high spatially resolved data. Improvement might be achieved by applying automatic bolus tracking during image acquisition to start the first post-contrast image acquisition at the best possible time. Similarly, a test bolus can be used to estimate the delay for the acquisition. A standard delay as used by several institutions allowing for the BAT might be beneficial. The influence of the temporal resolution is much more difficult to account for, since higher temporal resolution might yield worse results.

References: [1] Furman-Haran E, et al, JMRI 2001 [2] Kuhl K, et al; Radiology 1999 [3] Tofts PS, et al., MRM 1995. [4] Kelcz F, et al., AJR 2002; 179:1485-1492. [5] Boetes C et al, Radiology 1994