

MRI Evaluation of Decrease of Breast Density in the Contralateral Normal Breast of Patients Receiving Neoadjuvant Chemotherapy

J.-H. Chen^{1,2}, K. Nie¹, S. Bahri¹, R. S. Mehta³, C.-C. Hsu², F.-T. Hsu², H.-N. Shih², M. Lin¹, O. Nalcioglu¹, and M.-Y. L. Su¹

¹Center for Functional Onco-Imaging, UC Irvine, Irvine, CA, United States, ²China Medical University Hospital, Taichung, Taiwan, ³Department of Medicine, UC Irvine, Irvine, CA, United States

Background and Purpose: Systemic administration of chemotherapy not only affects the cancer but also other organs, including the ovary. Impairment of ovarian function induced by the toxicity of chemotherapy has been extensively studied. It has been shown that patients who were exposed to chemotherapy produced significantly less estradiol. Since the ovary secretes sex hormone, which regulates the glandular function of the breast, it is anticipated that suppression of ovarian function by chemotherapy will also induce secondary change in the breast tissue. However, this has not been reported, possibly due to the lack of quantitative methods that can evaluate the change of breast density reliably. We have developed a 3D MR-based method for quantitative measurement of breast density, and the method has been demonstrated to have a high reproducibility with measurement variations <3-4%. The purpose of this study was to investigate the change of breast density measured with quantitative MRI in the contralateral normal breast of patients receiving neoadjuvant chemotherapy (NAC).

Materials and Methods: In a period of three years (2003-2006), 54 patients (age 30-74, mean 47) who had received NAC and breast MRI were studied. The MRI studies were performed using a 1.5 T MR scanner. The non-contrast T1W images without fat suppression were used for measurement of the breast density. All patients had a baseline breast MRI examination prior to NAC and one to five follow-up MR studies during the course of the treatment. 46 had follow-up MRI studies after 1 or 2 cycles Doxorubicin and Cyclophosphamide (AC), 27 had MRI follow-up after 4 cycles AC, and they were referred as the AC cohort. Thirty-five patients had at least one AC follow-up as well as a final follow-up after completing the subsequent Taxane regimen, and they were referred as the AC+Taxane cohort. The quantification of breast density applied a fuzzy c-means (FCM) based segmentation algorithm with the b-spline curve fitting to obtain the breast boundary. The adaptive FCM was further applied for bias field correction to remove image intensity non-uniformities, and for segmentation of the fibroglandular tissue from the surrounding fatty tissue. The volume of fibroglandular tissue was calculated, and the percent density was obtained by normalizing to the total breast volume. The distributions of all variables (age, baseline density, and the percentage change in follow-up study compared to the baseline) were tested by the Kolmogorov-Smirnov test, and transformed to normal distribution before performing statistical analysis using multivariate regression models.

Results: The association with age was analyzed using the 46 patients who had 1-2 cycles AC follow-up. The results show that the baseline density decreases significantly with age (Fig. 1a). The percentage change normalized to the baseline density is also significantly dependent on age ($p=0.01$, Fig. 1b). All 11 patients younger than 40 years old showed decreased density. In contrast, among 7 post-menopausal patients older than 55 years old, 4 showed increased density and 3 showed decreased density ($p=0.01$). In the 35 patients in the AC+Taxane cohort, the average percentage change after the AC treatment is -10.0%, significantly lower compared to the baseline ($p=0.001$). After Taxane treatment, the average percentage change further decreased to -12.7% which was significant compared to the baseline ($p=0.001$), but not significant compared to the density before Taxane ($p=0.29$). The mean %density in this cohort is shown in Fig. 2. For all AC-cohort patients, the mean percentage reduction after 1-2 cycles AC was -8.0% ($p < 0.001$); and the mean percentage reduction after 4 cycles AC was -11.3% ($p < 0.001$). 19 patients had two F/U during AC. The mean percentage change was -9.4% after 1-2 cycles AC ($p=0.006$); -14.7% after 4 AC ($p=0.002$). When the density after 4 cycles AC was compared to the density after 1-2 cycles AC, the mean percentage reduction was -5.3% ($p=0.93$), which was not significant. An example of breast density reduction in the normal breast during NAC is shown in Fig. 3.

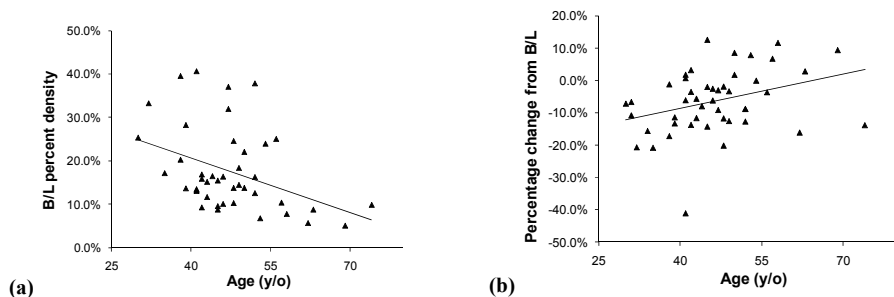


Figure 1. (a) The baseline MRI percent density decreases with age. (b) The percentage change is significantly dependent on age ($p=0.01$). Younger women show a greater reduction.

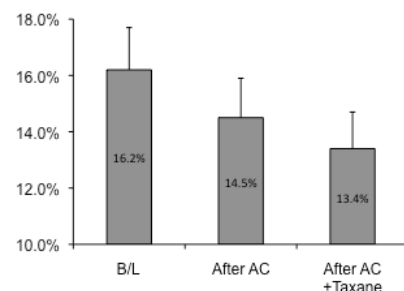


Figure 2. In 35 patients who had F/U after AC and AC+taxane treatment, the mean baseline density is 16.2%, decreases to 14.5% after AC, and continues to decrease to 13.4% after Taxane.

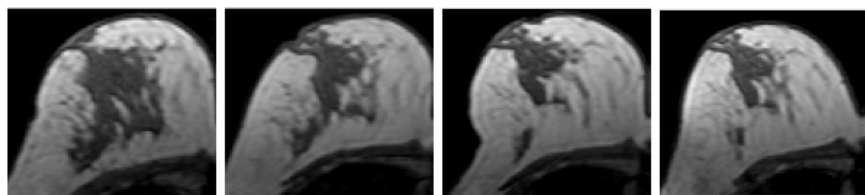


Figure 3. A 41 y/o woman with invasive ductal cancer in the left breast. Four images selected from the normal right breast taken at 4 time points (baseline, F/U-1, F/U-2, F/U-3) are shown. The density reduction in all follow-up MRI can be noted visually. The percentage reduction compared to the baseline density is 31% at F/U-1 after 2 AC, 35% at F/U-2 after 2 AC + 1 taxane, and 39% at F/U-3 after completing the NAC treatment.

Conclusions: We have demonstrated the feasibility of investigating the reduction of density following chemotherapy using a quantitative analysis method based on MRI. Patients receiving chemotherapy showed reduction of breast density, and that the effects were more pronounced in younger women than older (post-menopausal) women. The results suggest that the reduction of breast density after chemotherapy was possibly mediated through impaired ovarian function. The reduction could be clearly noted after 1 to 2 cycles of AC regimen. Although the density continued to decrease after 4 cycles of AC and the following Taxane regimen, the subsequent effect was smaller. It has been shown that changes in breast density may serve as a surrogate marker for predicting efficacy of chemoprevention such as Tamoxifen. Our results suggest that breast density also changes with chemotherapy, and the implication warrants further investigation.

Acknowledgement: This work was supported in part by NIH R01 CA90437, CA127927, R03 CA136071, and California Breast Cancer Research Program #14GB-0148, and National Science Council (Taiwan) 97-2314-B-039-031.