

Role of fMRI and DTI in assessing the efficacy of visual neurorehabilitation. Preliminary data

M. Bendini¹, I. Inches¹, M. Barabas², M. Prior³, M. Ronzon¹, S. Curtolo¹, D. Canonico⁴, C. Marzi², and F. Di Paola¹

¹Neuroradiology Department, Ca' Foncello Hospital Treviso, Italy, Treviso, Italy, ²Department of Neurological and Vision Sciences, University of Verona, Italy, ³Faculty of Psychology, University of Padua, Italy, ⁴Department of Physics, Ca' Foncello Hospital Treviso, Italy

Introduction

Homonymous visual field defects (HVFDs) are caused by postchiasmatic injury. The probability of occurrence of HVFDs following a stroke, trauma or surgery is high, around 20 - 30%. Recent studies suggest the possibility of rehabilitating HVFDs. In patients with HVFDs, f-MRI and DTI are two valid tools to evaluate postchiasmatic damage and to assess the efficacy of treatment.

Aim

The purpose of this preliminary study is to evaluate if the use of functional Magnetic Resonance Imaging (f-MRI) and Diffusion Tensor Imaging (DTI) can improve the accuracy in the diagnosis of HVFDs, in the choice of the treatment and in assessing the rehabilitation's outcome.

Materials and methods

We studied 6 patients with HVFDs who previously underwent neuropsychological and neurological evaluation. Neuroimaging was performed using a 1.5 T magnet. We applied a 3-D inversion-recovery T1 weighted sequence (TR/TE= 9,5/4,76 msec, slices = 160, 1 mm of slice thickness), a DTI sequence along 30 directions (TR/TE= 2800/96 msec, slices= 19) and a f-MRI (TR/TE= 3820/50 msec, 36 slices, 3 mm of slice thickness and 80 dynamics). Functional data were obtained while performing a visual and a phrase generation task. In the former patients viewed coloured pictures of objects or of geometric forms; in the second they were to visualize the object presented on the monitor and then generate a phrase semantically related to the object. Two patients of this group, after the first MRI evaluation, underwent a visual rehabilitation treatment. At the conclusion of the therapy, a second MRI study was performed to compare activation of the visual centers.

Results

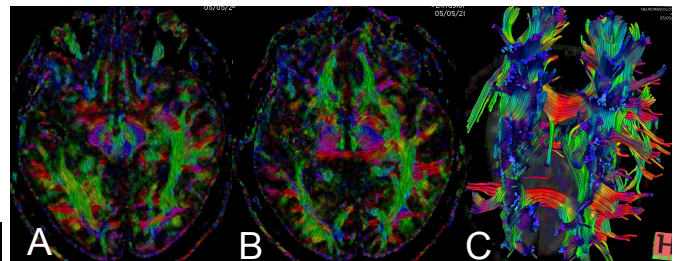
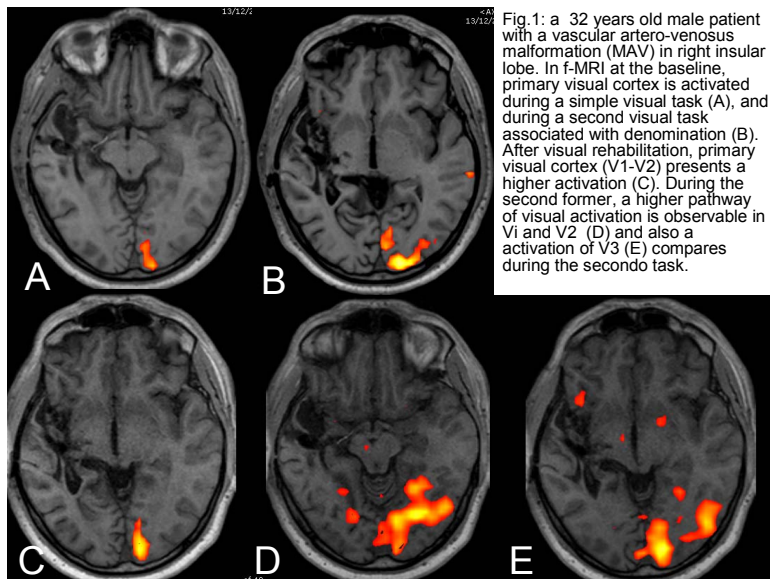
In all patients we did not find activation in the visual cortex (V1,V2) ipsilateral to the injury while the contralateral visual cortex showed a normal pathway activation.

In the treated patients, we observed a higher activation in the contralateral visual areas (V1, V2 and V3) associated to an improvement of the perimetry and neuropsychological tests specifically related to the rehabilitation treatment (Fig.1).

The DTI and tractography confirmed in all patients the presence of damage to the optical radiation (Fig. 2).

Conclusions

On the basis of these preliminary data, we can conclude that fMRI and DTI together with perimetry and neuropsychological tests represent an objective, useful, tool to establish the efficacy of the neurorehabilitation treatment.



References:

- Resolution of Homonymous Visual Field Loss Documented with Functional Magnetic Resonance and Diffusion Tensor Imaging. Masaki Yoshida, Masahiro Ida, Thien Huong, et al. J Neuro-Ophthalmol, Vol 26, No. 1, 2006.
- Brain Activity Associated With Stimulation Therapy of the Visual Borderzone in Hemianopic Stroke Patients. Randolph S. Marshall, John J. Ferrara, Anna Barnes, et al. Neurorehabil Neural Repair 2008; 22; 136-144.