

# Trimodal imaging and brain plasticity: MR diffusion tensor imaging supplements simultaneously acquired FET-PET and MP-RAGE of human brain tumour imaging

N. J. Shah<sup>1,2</sup>, I. Neuner<sup>1,2</sup>, J. B. Kaffanke<sup>1</sup>, Y. Kupriyanova<sup>1</sup>, K.-J. Langen<sup>1</sup>, and H. Herzog<sup>1</sup>

<sup>1</sup>Institute of Neurosciences and Medicine 4, Medical Imaging Physics, Forschungszentrum Jülich GmbH, 52425 Jülich, Germany, <sup>2</sup>Faculty of Medicine, Department of Neurology, RWTH Aachen University, 52074 Aachen, Germany

## Abstract

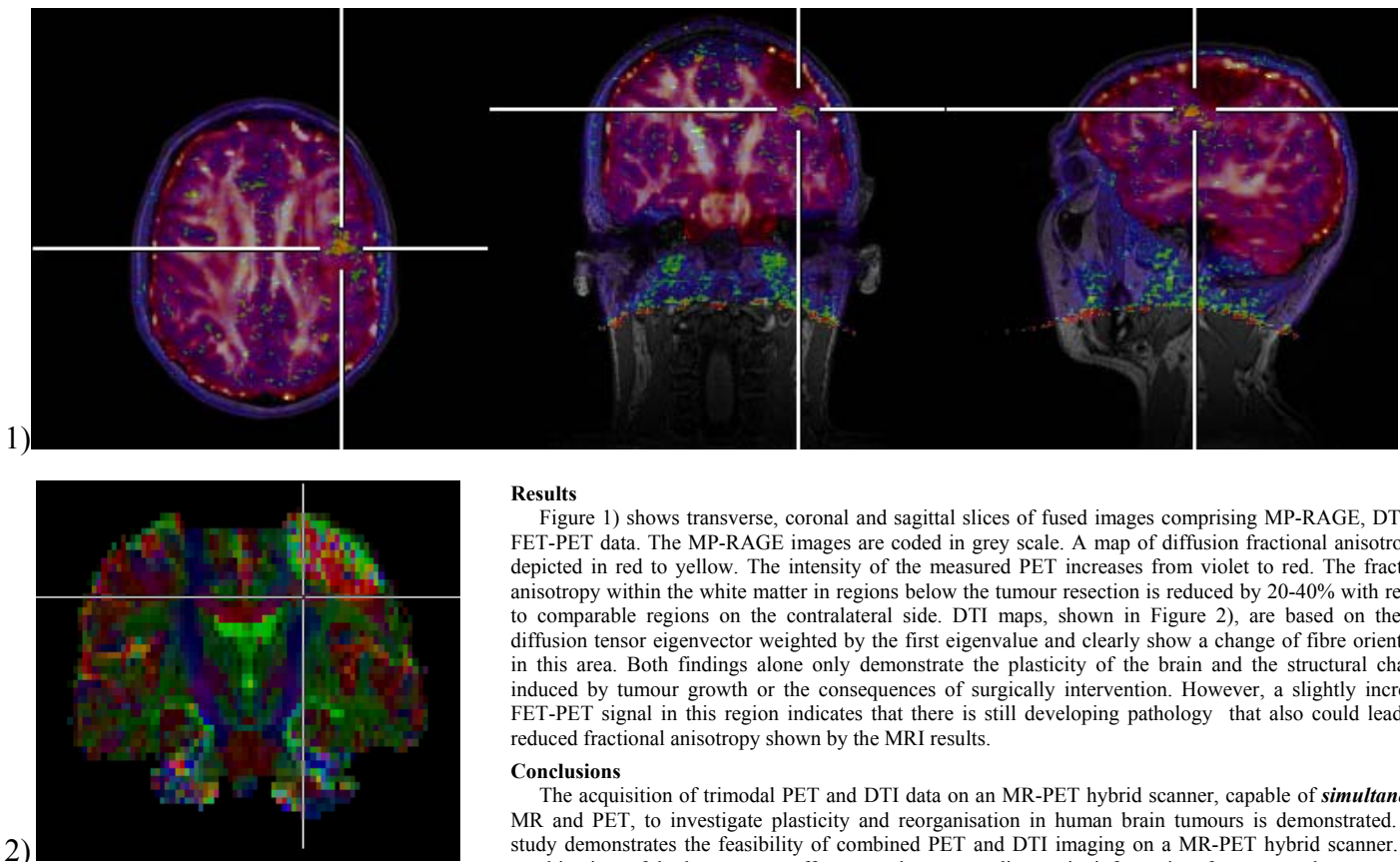
PET imaging is well established for the diagnosis of brain tumours. Its metabolic specificity delivers valuable information about the malignancy and the extent of tumour tissue. Tumour growth forces the brain to reorganize itself to compensate for the lost areas. It has been shown that DTI is a valuable tool to demonstrate the plasticity of the brain and it therefore offers information about the reorganization caused by tumour growth as well as surgical intervention [1, 2]. The acquisition of trimodal PET, MP-RAGE and DTI data on an MR-PET hybrid scanner, capable of *simultaneous* MR and PET, to investigate plasticity and reorganisation in human brain tumours is demonstrated.

## Introduction

Positron emission tomography is a widely used and established tool for clinical tumour diagnosis. The method complements CT and MR imaging with respect to its metabolic specificity and helps to judge the malignancy and extent of the tumour tissue. The new technologies comprising MR-PET hybrid scanners have the advantage of measuring PET and MRI data that are intrinsically co-registered in time and space [3,4]. This reduces measurement time and greatly aids patient compliance. DTI is a valuable tool to demonstrate the plasticity of the brain offering insights into the reorganization brought about by tumour growth and / or surgical intervention [1, 2]. This study is the first to demonstrate the feasibility of trimodal imaging combining anatomical (MP-RAGE), structural (DTI), and metabolic-specific, functional information (FET-PET) for the investigation of brain tumours in humans.

## Methods

PET was performed using the amino acid O-(2-[<sup>18</sup>F]Fluorethyl)-L-Tyrosin (FET)<sup>1</sup> [5,6]. After injection of 200 MBq FET, a combined MR-PET scan was performed on a Siemens 3 Tesla MAGNETOM Tim-Trio system equipped with a BrainPET insert. The BrainPET scan time was 35 min and MRI was performed simultaneously. Anatomical images were acquired with a T<sub>1</sub> weighted MP-RAGE sequence within a scan time of 9 min. The matrix size was 256x256x192 to achieve a 1mm isotropic resolution. DTI data were acquired with a double spin-echo diffusion weighted EPI sequence using GRAPPA with acceleration factor 2. The echo time was 86 ms and the repetition time was 6200 ms. Here, the matrix size was 128x128.50 slices with voxels of 1.9x1.9x2.85 mm<sup>3</sup> were acquired. A total of 30 diffusion gradient directions were used with a b-value of 1000. Four averages were taken in 13 min scan time. The DTI data were processed using FSL [7]. Fused images were produced with VINCI. Results are shown from a representative subject. The patient (44 yrs, male) had an extirpated oligoastrocytoma WHO<sup>o</sup> III and was included in a study accepted by the responsible ethic commission; he gave written, informed consent prior to participation.



## Results

Figure 1) shows transverse, coronal and sagittal slices of fused images comprising MP-RAGE, DTI and FET-PET data. The MP-RAGE images are coded in grey scale. A map of diffusion fractional anisotropy is depicted in red to yellow. The intensity of the measured PET increases from violet to red. The fractional anisotropy within the white matter in regions below the tumour resection is reduced by 20-40% with respect to comparable regions on the contralateral side. DTI maps, shown in Figure 2), are based on the first diffusion tensor eigenvector weighted by the first eigenvalue and clearly show a change of fibre orientation in this area. Both findings alone only demonstrate the plasticity of the brain and the structural changes induced by tumour growth or the consequences of surgically intervention. However, a slightly increased FET-PET signal in this region indicates that there is still developing pathology that also could lead to a reduced fractional anisotropy shown by the MRI results.

## Conclusions

The acquisition of trimodal PET and DTI data on an MR-PET hybrid scanner, capable of *simultaneous* MR and PET, to investigate plasticity and reorganisation in human brain tumours is demonstrated. The study demonstrates the feasibility of combined PET and DTI imaging on a MR-PET hybrid scanner. The combination of both scanners offers complementary diagnostic information for pre- and post-surgical progression control of brain tumours. As demonstrated here, the benefits of a hybrid system for the investigation of brain plasticity, as a consequence of tumour growth and/or surgery, are: improved patient compliance, a significant reduction in measurement time, and the spatial and temporal co-registration of PET and MR data.

## References

- [1] Stadlbauer, A., et al., AJNR Am J Neuroradiol, 2007. 28(3): p. 462-9.
- [2] Stadlbauer, A., et al., Acta Neurochir (Wien), 2009. 151(9): p. 1061-9.
- [3] Schlemmer HP et al. Radiology 2008;248:1028-35
- [4] Herzog, H., et al. NeuroImage (in press) doi:10.1016/j.neuroimage.2009.10.036,
- [5] Journal of Nuclear Medicine, 1999. 40(1): p. 205-212,
- [6] Nuclear Medicine and Biology, 2003. 30(5): p. 501-508,
- [7] S.M. Smith, et al., NeuroImage, 23(S1):208-219, 2004.