

Role of Diffusion Tensor Imaging in Diagnosis of Medial Temporal Lobe Epilepsy

H. ALI¹, M. MOHAMED², Y. ABDULLAH³, A. GABER³, and Y. ABBAS³

¹AIN SHAMS UNIVERSITY HOSPITALS, CAIRO, Egypt, ²JOHNS HOPKINS UNIVERSITY SCHOOL OF MEDICINE, BALTIMORE, MARYLAND, United States, ³AIN SHAMS UNIVERSITY HOSPITALS

Background and purpose: Frequently, we are facing epilepsy studies which appear normal on conventional magnetic resonance imaging (MRI) even after performing special MR epilepsy protocol. Modern MR techniques are helpful in assessment of patient with seizures (1-3), especially in preoperative assessment of those cases with intractable epilepsy. This study is aiming to assess the role of diffusion tensor imaging (DTI) in patients with medial temporal lobe epilepsy (MTLE).

Material and Methods: Ten patients with MTLE and 10 healthy subjects had performed conventional MRI epilepsy protocol including thin cuts coronal oblique IR images for temporal lobes, FLAIR, fractional anisotropy (FA) and apparent diffusion coefficient (ADC) of special regions specially hippocampus bilaterally using 1.5 T MR unit (Intera; Philips Medical System, Best, Netherlands) Qualitative assessments were done for the conventional MR images as well as the DTI color maps using offline workstation (extended work space “EWS”) (Release 2.5.3.0: Dell, Round Rock, Tex). MR tractography was then performed for fornix, cingulum, inferior longitudinal fasciculus (ILF), inferior fronto-occipital fasciculus (IFOF), corpus callosum, middle cerebellar peduncle, and corticospinal tract. FA and ADC values were measured and then compared quantitatively as an assessment of pertinent regions. All data was correlated with the clinical and advanced EEG of the patient.

Results: There was no significant quantitative or qualitative difference in diffusivity or FA measurements between the sides in controls. The patient group, however, had significantly decreased FA values and increased ADC values in the hippocampus as well as the basal ganglia ipsilateral to the seizure focus, and there were mild similar changes in the cingulum, ILF and to a lesser extent in other tracts ipsilateral to seizure focus as suggested by the clinical and EEG findings (Figure 1) (Table 1). Moreover, in some cases, the DTI data also revealed contralateral similar (but less impressive) abnormalities of FA and diffusivity values when compared with the controls.

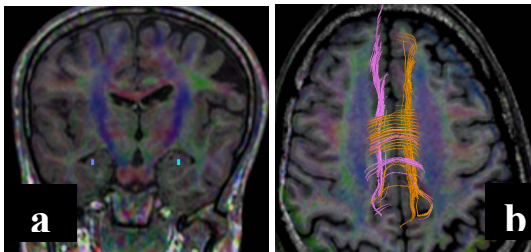


Figure 1: Nine year old male with epilepsy. Conventional brain MRI was unremarkable (not shown). a) DTI color map overlaid on coronal FLAIR, b) DTI tractography for cingulum overlaid on axial image. ROIs were plotted on the hippocampus and ILF on both sides. There is substantial difference in the FA and diffusivity values between both sides, with decreased FA and increased ADC values on the right side in the hippocampal regions and cingulum. Findings are suggestive of right mesial temporal sclerosis. These were consistent with advanced EEG findings.

Table 1: Decreased FA values and increased ADC values in the right hippocampus and ILF of the same patient

Hippocampus	FA	ADC ($10^{-3} \text{mm}^2/\text{s}$)	Cingulum	FA	ADC ($10^{-3} \text{mm}^2/\text{s}$)
Left	0.21 ± 10^{-3}	0.87 ± 10^{-3}	Left	0.471 ± 10^{-3}	0.810 ± 10^{-3}
Right	0.09 ± 10^{-3}	1.05 ± 10^{-3}	Right	0.432 ± 10^{-3}	0.909 ± 10^{-3}

Conclusion: DTI of the brain coupled with tractography provides essential information in challenging cases of MTLE in which conventional MRI and EEG showed no abnormality. The added quantitative value of DTI tractography is useful in proper evaluation, therapy and follow up of these cases.

References:

1. Assaf et al. Diffusion Tensor Imaging of the Hippocampal Formation in Temporal Lobe Epilepsy. American Journal of Neuroradiology, October 2003, 24:1857-62.
2. Jellison et al. Diffusion Tensor Imaging of Cerebral White Matter: A Pictorial Review of Physics, Fiber Tract Anatomy, and Tumor Imaging Patterns. American Journal of Neuroradiology, March 2004, 25:356-69.
3. Bartlett et al.. High-resolution diffusion tensor imaging of the hippocampus in temporal lobe epilepsy. Epilepsy Research, 2006; 71(2-3):102-106.