

# A Virtual Reality System for Neurosurgery: Integrated Brain Tumor With Peri-tumoral Neuroanatomy

C-Y. Lo<sup>1</sup>, W-Y. Guo<sup>2</sup>, K-H. Chou<sup>3</sup>, and C-P. Lin<sup>1</sup>

<sup>1</sup>Institute of Biomedical Imaging and Radiological Sciences, National Yang Ming University, Taipei, Taiwan, <sup>2</sup>Department of Radiology, Taipei Veterans General Hospital, Taipei, Taiwan, <sup>3</sup>Institute of Biomedical Engineering, National Yang Ming University, Taipei, Taiwan

## Introduction

In neurosurgery, the relationship among tumor mass and peri-tumoral structures including peri-tumoral edema are important for planning surgical trajectory and crucial for diagnosis, tumor excision, and post-surgical outcome [1]. Conventionally, T2WI and Gadolinium(Gd)-T1WI provide the information of, tumor mass, and peri-tumoral edema. The recent development of diffusion tensor MRI (DTI) has shown its feasibility in grading tumor [2], monitoring therapeutic effects [3], and clinical outcome [4]. Furthermore, DTI also provides the anatomical information of peri-tumoral microstructures, which might be deviated, infiltrated, and destroyed by a brain tumor [5]. Virtual reality (VR) is a powerful technique that can provide 3D display and even interaction between operators [6, 7]. In this study, a VR environment for integrating neuroanatomy was developed. It was aimed to clarify the relationship between tumor mass, peri-tumoral edema and brain tissues, and surrounding neural tracts derived from DTI for facilitating neurosurgical trajectory design and optimizing therapeutic outcome.

## Materials and Methods

A patient (43 years-old, female) has a brain tumor which affected motor pathway (corticospinal tract) was recruited as an example. MR data were acquired at 1.5T MR system (Excite II; GE Medical Systems, Milwaukee, Wis, USA) with an 8 channels head coil. T1WI before and after the Gd-DTPA administration (0.1 mmol Gd-DTPA/kg of body weight) with TR/TE= 550/15 ms, field of view (FOV)=24x24 cm<sup>2</sup>, matrix=325x256 and pre-contrast T2WI with TR/TE = 3000/90 ms using fast spin-echo sequences with same pixel size were routine sequenced. DTI was performed using single-shot spin-echo echo planar imaging sequence with TR/TE = 17000/70.4 ms, FOV=26x26 cm<sup>2</sup>, slice thickness=2.2mm, matrix=128x128, noncollinear diffusion directions=13, b = 1000 s/mm<sup>2</sup>, NEX = 6. With 2 reference images, the spherical symmetric diffusion tensor MR imaging sequence was used to minimize the cross-term effect and to optimize the signal-noise-ratio [8, 9].

Brain tumor and edema were segmented manually on Gd-T1WI and T2WI respectively and reconstructed into 3D display. Fiber tracking was carried out by the FACT algorithm [10] with fractional anisotropy (FA) threshold of 0.2 and angular limitation of 60 degree. With anatomic images or diffusion indices map including T1WI, T2WI, FA, and mean diffusivity (ADC), the 3D morphological visualization was integrated in a VR system. The 3D stereo tractography was programmed by Borland C++ Builder 6.0 and OpenGL API. Based on the different viewpoints of human eyes, the VR system was developed via the projection-based stereo display system. The 3D stereo image (the two different phase images superimposed) was projected on the non-depolarizing (silver) screen by two projectors with polarizing filter. Through linear polarized 3D glasses, the viewings of the user's right and left eyes would be slightly different and the stereo image would be produced from the user's viewpoint.

## Results

In this VR system, neuroanatomy around tumor mass and peri-tumoral edema was displayed in 3D stereo. Users can interact with this system by selecting different region-of-interest (ROI) to show different neural tracts or selecting various FA or ADC threshold to show the tissue integrity and related neural tracts. As shown in figure 1, the user can interact with the VR system directly by using mouse cursor. In figure 2, different color was assigned to display the brain tumor (orange region), peri-tumoral edema (aqua region), its surrounding motor pathways (red lines), and motor pathways in contralateral hemisphere (green lines) for reference. The background anatomy was FA map. Users can freely manipulate the related images to design a neurosurgery trajectory; simulate tumor removal and tissue dissection.

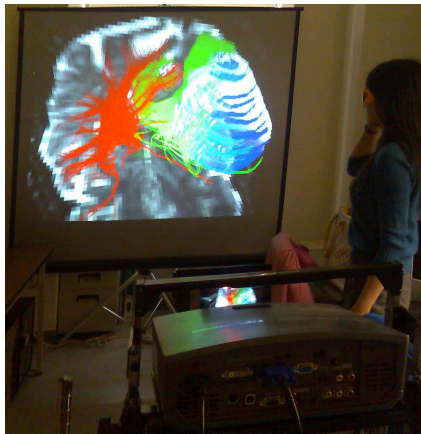


Fig.1 Brain tissues were 3D stereo displayed by the VR system, interactively.

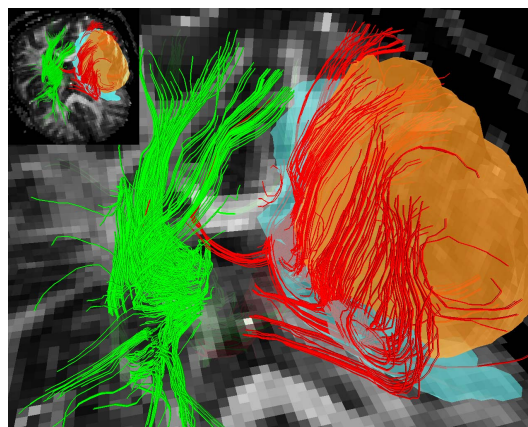


Fig.2 Different color was assigned to display the brain tumor (orange region), peri-tumoral edema (aqua region), its surrounding motor pathways (red lines), and motor pathways in contralateral hemisphere (green lines). Relationship between brain tumor and surrounding tissues can be further clarified.

## Discussion

A 3D VR environment integrated with T1WI, T2WI, and DTI was developed. Tumor mass as well as the peri-tumoral edema, brain tissues and relevant neural tracts can be 3D stereo displayed for designing a neurosurgical trajectory. Take this patient as an example, the brain tumor deviated, instead of destroyed, the surrounding motor neural tracts. It was confirmed clinically with intact presurgical motor functions. Neurosurgical trajectory was designed under the guidance of this system with the anticipation of a better post-surgical outcome. In conclusion, this 3D VR can provide a stereo interaction between images and be helpful to optimizing neurosurgical management.

## Acknowledgement

This study was supported in part by Taiwan National Science Council grant NSC 98-2923-B-010 -001 -MY3

## References

- [1] Coenen, V.A., et al., 2001. 49(1): p. 86-92; discussion 92-3. [2] Bastin, M.E., et al., Proc Natl Acad Sci U S A, 2005. 102(46): p. 16759-64. [3] Hamstra, D.A., et al., Proc Natl Acad Sci U S A, 2005. 102(46): p. 16759-64. [4] Fang-Ying Chiu, et al., Proc. Intl. Soc. Mag. Reson. Med., 2006. 14 (3155). [5] Jellison, B.J., et al., AJNR Am J Neuroradiol, 2004. 25(3): p. 356-69. [6] Tarr, M.J. and W.H. Warren, Nat Neurosci, 2002. 5 Suppl: p. 1089-92. [7] Suzuki, Y. and M. Kobayashi, 2005. 25(1): p. 44-47. [8] Jones, D.K., M.A. Horsfield, and A. Simmons, Magn Reson Med, 1999. 42(3): p. 515-25. [9] Neeman, M., J.P. Freyer, and L.O. Sillerud, Magn Reson Med, 1991. 21(1): p. 138-43. [10] Mori, S., et al., Ann Neurol, 1999. 45(2): p. 265-9.