

Comparison of Limbic Regions FA Using Tractography-defined ROIs in AD and MCI

D. H. Hwang¹, S. Tsao¹, and M. Singh¹

¹Radiology and Biomedical Engineering, University of Southern California, Los Angeles, CA, United States

Introduction:

The fornix and cingulum (limbic regions) are suspected of being affected by mild cognitive impairment (MCI) and Alzheimer Disease (AD). Recent studies have reported observable reductions in FA of the cingulum between normal and AD populations. Most studies resort to manual tracing of the anatomy in patient acquisition space. Objective isolation of the fornix and cingulum has remained elusive. The purpose of this study was to (a) bring DTI including tractography to a common template space, (b) define the fornix and cingulum objectively using tractography, and (c) examine the FA changes among normal control, MCI and probable AD populations.

Method:

Data were acquired on a 3T GE scanner from three populations (26 normal control, 16 MCI, and 13 AD probable) as classified by neuropsychological testing. Multi-slice (2.04 x 2.04 x 4 mm³ voxel size, 4 mm thick slices no gap) data were acquired using 25 encoding gradient directions at b-values of 0 and 1000 sec/mm² with an acquisition matrix of 128x128. Anatomical data were acquired using a 256 x 256 acquisition matrix employing a SPGR sequence (1 x 1 x 1 mm³ voxel size, 1 mm thick slices no gap) with TE=3.128ms, TR=7.832ms and TI=450ms.

SPM8 was used to co-register the DTI b-value = 0 data to the SPGR images. A custom template was created using the 26 normal control scans. All anatomical scans were normalized to the template using SPM8's DARTEL suite. The custom template was then spatially normalized to MNI space. The three step transformation allows for the FA map to be warped into MNI space. Tractography was conducted in subject space using normalized seeds inversely mapped from the MNI space and individual tracts were mapped from subject space to MNI space thereby avoiding the problems associated with spatial warping of diffusion tensors.

A single set of ROIs were defined in MNI space and applied to the normal control group whole-brain tractography to isolate the fornix and cingulum. Four processing masks were defined (left fornix, right fornix, left cingulum, and right cingulum) as voxels where tracts overlapped in at least 50% of the control group. A voxel-based comparison of the t-score statistics among the FA map difference of the three different populations was conducted using the four masks to highlight changes observed in the fornix and cingulum tracts.

Results and Conclusions:

SPM8's DARTEL suite provided a much improved normalization of the aged brain populations. Visual inspection of the filtered fornix and cingulum tracts confirmed greatly improved alignment when compared to previous results. The t-score comparisons (**Fig. 1 and 2**) visually illustrate areas where FA in one population is higher than the other. There appears to be a progressive degeneration of the fornix and the cingulum. The right and left fornix branches both exhibit pattern of damage which begins at the hippocampal end of the fornix and propagates toward the hypothalamus with right greater than left reduction in FA. The cingulum shows less damage, but does appear to be show progressive damage extending to the posterior end, more in right than left. The complete posterior cingulum portion could not be reliably identified in the common space for all subjects, suggesting a need for further improvement of normalization in AD. These preliminary results shows promise in tracking axonal damage with the progression of Alzheimer Disease. The right greater than left reduction of FA in the fornix and cingulum is consistent with several reports of white matter atrophy and hypometabolism in AD (e.g., Villain, N. et. al., J. NeuroSci. 28(24):6174-6181).

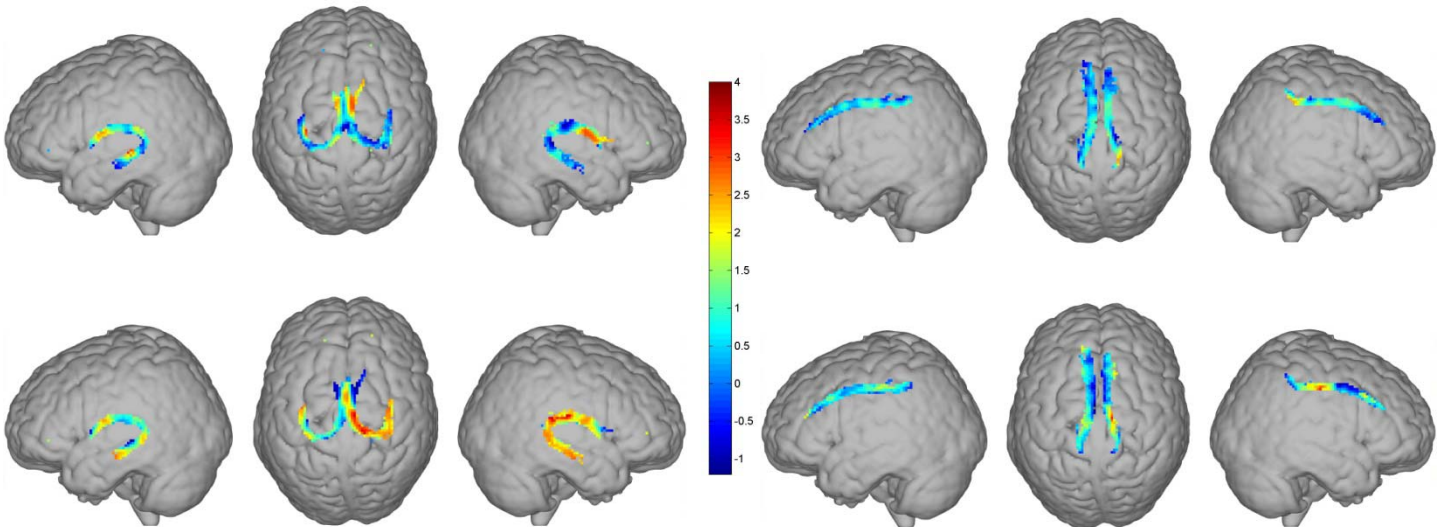


Figure 1: Fornix FA t-Score Comparison. MCI > AD (top row) NC > MCI (bottom row). Colors denote the t-score difference between the mean FA of the various populations.

Figure 2: Cingulum FA t-Score Comparison. MCI > AD (top row) NC > MCI (bottom row)