

Chemical Shift Imaging in the Head and Neck at 3T: Initial Results

D. K. Yeung¹, D. K. Fong¹, Q. Chan², and A. D. King¹

¹Diagnostic Radiology and Organ Imaging, The Chinese University of Hong Kong, Shatin, N.T., Hong Kong, ²MR, Philips Healthcare, Wanchai, Hong Kong

Background

Chemical shift imaging (CSI) is a useful technique to examine large heterogeneous lesions to show the spatial distribution of key metabolites for clinical applications. Performing CSI in the head and neck may be challenging due to large susceptibility differences between tissues in the skull-base. Sub-optimal shimming in the of CSI data acquisition process leads to spectral peak broadening and frequency shifts. Furthermore, studies have shown that spectral linewidth is increased at 3T compared to 1.5T [1] due to lower magnetic field homogeneity at higher fields, making the prospects of performing CSI in the head and neck even harder.

Introduction

Proton CSI can be used to detect elevated choline containing-compounds in cancers of the brain [2], prostate [3], and breasts [4]. Elevated choline has also been documented using single voxel proton MRS in head and neck squamous cell carcinoma and percentage changes in Cho levels after chemoradiotherapy has been suggested to serve as a marker of residual cancer in a post-treatment mass [5]. To study large heterogeneous lesions in the head and neck, a multi-voxel acquisition method is preferred. However, large susceptibility differences in the skull-base may require new shimming strategies to enable CSI to be performed. Our aim in this study was to test whether the use of an anti-susceptibility device might improve local shimming so that reliable choline maps could be obtained in the head and neck.

Materials and Methods

This study was performed on a 3T whole-body MR imaging system (Achieva X-series, Philips Healthcare, Best, the Netherlands) using a 16-channel neuro-vascular coil for signal reception. Thirteen consecutive patients with head and neck cancer were recruited and consented to undergo CSI using a 2D point-resolved spectroscopic sequence (PRESS) (TR/TE 2000/144 ms; slice thickness 10 mm; matrix 24 × 24, FOV 24 cm, NEX 1). An anti-susceptibility device (Neck Sat Pad, Magmedix, Inc.) filled with liquid perfluorocarbon (PFC), wrapped around patients' neck was used to improve local magnetic field homogeneity. A water bottle phantom (Ø 12 cm, length 19 cm) containing 4 small choline samples (Ø 1.2 cm, length 4.7 cm) at a concentration of 10 mM, 5 mM, 2.5 mM and 1.25 mM was constructed to test the linewidth improvement using the anti-susceptibility device. Same scanner specific automatic shimming method (pencil beam) with first-order and second-order shim corrections was employed throughout.

Results

Successful CSI was obtained in 9 patients (nasopharyngeal carcinoma (NPC), n = 5; squamous cell carcinoma (SCC), n = 2; Schwannoma, n = 2) presented with tumors ranged from 2 – 8.6 cm of maximum diameter. Figure 1 shows an example of a successful choline map from a patient presented with a metastatic NPC node; the shim volume was shown by the green rectangle. Four patients who failed CSI were primary NPC (n = 2), palatal SCC (n = 1) and hard palate mucoepidermoid carcinoma (n = 1). Full-width half maximum (FWHM) of the water peak measured from the water phantom without and with anti-susceptibility device decreased from 6.1 Hz to 4.3 Hz (30% reduction) (Fig. 2). Choline signal was detectable from all samples except the one at the lowest concentration.

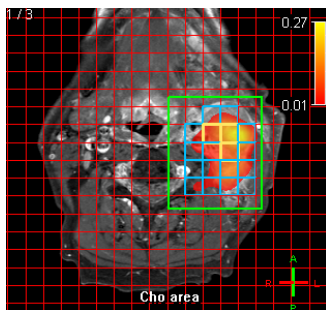


Fig. 1

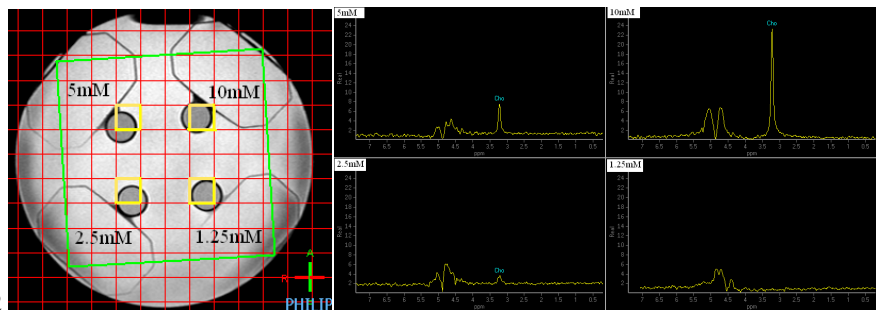


Fig.2

Conclusion

Our initial results showed that CSI in the head and neck is feasible with a success rate of about 70%. Optimal shimming could not be achieved in cases when the tumors were located in the palate or in the nasopharynx where susceptibility differences were probably large. Another probable cause of CSI failure was patient swallowing during data acquisition. Employing an anti-susceptibility device around the neck did improve local shimming demonstrated by a 30% narrowing of the water peak linewidth. More research needs to be done to develop this technique further and to identify potential clinical applications.

Reference

[1] Barker PB et al. *Magn Reson Med* 2001; 45: 765-769. [2] Hermann EJ, Hattingen E, Krauss JK, et al. *Stereotact Funct Neurosurg*. 2008;86(5):300-307. [3] Hricak H. *Br J Radiol*. 2005;78:S103-11. [4] Jacobs MA, Barker PB, Argani P, et al. *J Magn Reson Imaging*. 2005;21(1):23-28. [5] King AD, Yeung DK, Yu KH, et al. *Eur Radiol*. 2009 Aug 5.