

Effects of continuously high levels of corticosteroids on mouse hippocampus – a longitudinal in vivo MRI study

D. Suci¹, A. E. Scheenstra², J. Dijkstra², M. S. Oitzl³, and L. van der Weerd^{1,4}

¹Radiology, LUMC, Leiden, Netherlands, ²Radiology - Image processing, LUMC, Leiden, Netherlands, ³Medical Pharmacology, LACDR, Leiden, Netherlands, ⁴Anatomy, LUMC, Leiden, Netherlands

Introduction: Chronic exposure to stress hormones (hypercorticism) is involved in a series of debilitating disorders, such as Cushing's syndrome and depression. The impact of these disorders on human cognitive functions, social and professional life asks for determination of causal factors. The present study performs for the first time a longitudinal MRI investigation on mice subjected to hypercorticism.

Methods: *Mouse model:* High stress hormone levels were reached by implantation on Day 0 of a continuous corticosterone-releasing pellet (highCORT, n=10) or a placebo cholesterol pellet (CONTROL; n=10) subcutaneously in 12 w/o male C57BL/6J mice. Corticosterone from the pellets was expected to last on average 14 days.¹

MRI: T2W MRI scans were taken of the mouse brain with a Bruker 9.4 T system. Parameters were: TE = 12.760ms, TR = 4000ms, RARE factor = 4, FOV = 18mm², matrix = 200 x 200, 30 0.25mm slices, 12 averages. The scans were taken prior to (pre-exposure; Day -7), during (exposure; Day 15) and post (recovery; Day 22) exposure. Blood samples were collected by tail incision to confirm hypercorticism. The scans were analysed in two ways: by volumetric analysis involving manual delineation of the hippocampi (ImageJ) and subsequent statistical analysis using SPSS; and by applying a quantitative group-wise comparison of the deformation fields which were obtained by non-rigid registration of all the subjects belonging to one experimental group to an average control image. The statistical comparison was done using a 3D Moore-Rayleigh test, after Bonferroni correction.²

Results: The plasma corticosterone profile (Figure 1) shows that highCORT mice had significantly higher levels of corticosterone during exposure than the CONTROL group. These mice did not respond endocrinologically to the challenge (decapitation) on day 30. In contrast, the CONTROL mice displayed normal plasma corticosterone values at all times, and a high reactivity to the challenge. These data confirm the success of the treatment. The highCORT mice showed an overall decrease in total hippocampal volume during exposure and recovery (Figure 2). The volume loss appeared to normalize during recovery, as left and right hippocampi displayed some growth, with the right hippocampus increasing more in volume than the left. Interestingly, the CONTROL group displayed continuous hippocampal growth. The group-wise comparison was performed within the highCORT group, between the pre-exposure and the exposure/recovery data. Its outcome supports the volumetric results: following exposure it displayed a larger deformation along the left corpus callosum (compared to the pre-exposure state) and smaller along the right corpus callosum (Figure 3).

Conclusions: Volumetric T2W MRI and quantitative group-wise comparison using deformation fields demonstrated that chronic hypercorticism in mice leads to shrinkage of the hippocampus, which is at least partially reversible after recovery. We suggest that longitudinal MRI together with cognitive tests will allow finding novel targets for treatment of stress-related diseases.

1. Dalm S, Brinks V, van der Mark MH, de Kloet ER, Oitzl MS (2008) Non-invasive stress-free application of glucocorticoid ligands in mice. *J Neurosci Methods* 170:77-84

2. Scheenstra AE, Muskulus M, Staring M, van den Maagdenberg AM, Lunel SV, Reiber JH, van der Weerd L, Dijkstra J (2009) The 3D Moore-Rayleigh test for the quantitative groupwise comparison of MR brain images. *Inf Process Med Imaging* 21:564-575

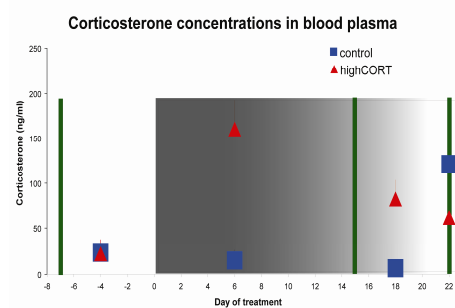


Figure 1: Evolution of the plasma corticosterone in highCORT (red) and CONTROL (blue) groups depending on treatment. The treatment started on day 8, and ended with decapitation on day 30. The green bars mark the moments when MRI measurements were performed.

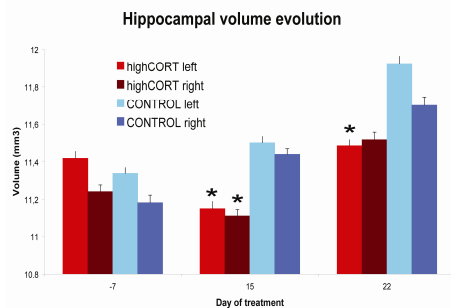


Figure 2: Evolution of left and right hippocampal volume depending on the treatment. The bars display the average volume in mm³ and the standard error associated with the average. The star (*) marks a significant difference between the highCORT and the CONTROL group (1 tail mean comparison test).

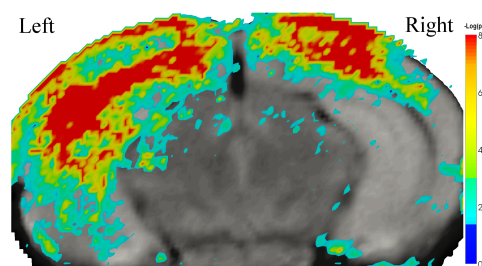


Figure 3: Computerized maps displaying treatment-dependent changes in the brain structure in the highCORT group, during exposure in comparison to the pre-exposure state. The significant changes after Bonferroni correction ($p < 10^{-8}$) are plotted in red.