

## A transversal and longitudinal MRI study in patients with cervical dystonia using VBM analysis.

P. Totaro<sup>1</sup>, E. Raz<sup>2</sup>, G. M. Contessa<sup>2</sup>, F. Tona<sup>2</sup>, G. Fabbrini<sup>2</sup>, A. Berardelli<sup>2</sup>, C. Colosimo<sup>2</sup>, L. Bozzao<sup>2</sup>, and P. pantano<sup>3</sup>

<sup>1</sup>Department of Neurological Sciences, Sapienza University of Rome, Rome, Italy, <sup>2</sup>Sapienza University of Rome, Rome, Italy, <sup>3</sup>Sapienza University of Rome, Rome, Italy, Italy

Primary adult onset focal dystonia is generally not associated with apparent morphological changes in central nervous system structures. Nevertheless, the use of non conventional neuroimaging techniques is increasingly challenging this belief by detecting brain abnormalities in those areas which have been hypothesized to be functionally involved in the pathophysiology of this disorders. In this study we evaluated the local concentration of gray matter (GM) by voxel-based morphometry (VBM).

We enrolled 19 patients with cervical dystonia (mean age 53.2 [SD=11.2] years). Secondary or inherited dystonia were excluded. Severity of symptoms was measured by means of the Tsui scale, with an average value of 10 [SD=3]. The mean duration of symptoms was 12.7 [SD=6.5] years. All patients with cervical dystonia received botulinum toxin injections following standard treatment regimens.

All patients underwent a detailed neurological examination and MRI at the moment of the maximal benefit (two to three weeks of the last botulinum injection). Twelve patients were studied again on average 63 [SD=5] months later. There were 3 men and 9 women, with a mean age of 56 [SD=13] years. Severity of dystonia was unchanged between the two MRI studies.

Twenty-eight healthy volunteers (17 women and 11 men; mean age 47.5 [SD=15.6] years) with no known brain abnormalities and no neurological symptoms were recruited as controls.

All the subjects were imaged with a 1.5 T scanner with an axial dual-echo turbo spin echo sequence and a 3D-T1-weighted sequence on 150 contiguous axial 12 mm-thick sections.

3D-T1 images underwent automated segmentation in SPM5 to yield GM, white matter (WM) and cerebrospinal fluid (CSF) images. A mask was constructed on the aal (Automated Anatomical Labelling) map using MRIcro software, by selecting regions belonging to the sensory-motor network.

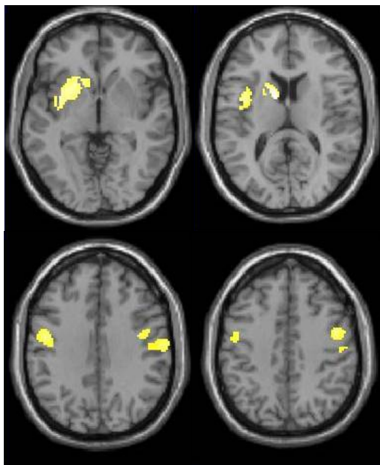
Voxelwise comparison of the GM volumes between patients and controls was performed using an analysis of covariance (ANCOVA), corrected for age. Voxelwise comparison between the baseline and the follow-up studies of the 12 patients was carried out by means of a two-paired t-test. Statistical threshold was settled at  $p < 0.05$  corrected for multiple comparisons at cluster level.

Global GM volumes at baseline were slightly but significantly ( $p = 0.01$ ) lower in the patient group with respect to the control group (591.95 [SD: 65.83] vs 654.82 [SD: 86.17]). No differences between groups were found in both global WM and CSF volumes.

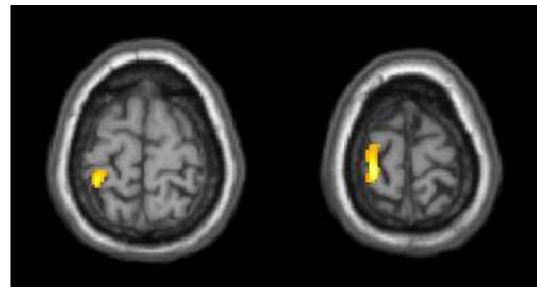
The voxel-wise comparison of the local GM concentration revealed a significant GM reduction in the left caudate head and putamen, and in the premotor and primary sensory motor cortices bilaterally in the patient group with respect to healthy controls. This finding was correlated neither with patients' age nor severity or disease duration.

The longitudinal VBM evaluation of 12 patients who were studied twice showed a significant further decrease in the GM concentration in the left primary sensory motor cortex at the follow-up with respect to the baseline study.

These results suggest a possible role of the subcortical-cortical motor network in the pathophysiologic mechanisms of primary dystonia.



SPM demonstrating the structural decrease in gray matter concentration in 19 patients with dystonia with respect to 28 healthy controls (ANCOVA). Results are superimposed in yellow on the slices of a T1-weighted mean-image (four axial views passing at z coordinates of -6, 12, 34, 42). Clusters significant at  $p < 0.05$  corrected for multiple comparison were observed in the left caudate head and putamen, and in the premotor and primary sensory motor cortices bilaterally.



SPM demonstrating the structural decrease in areas of gray matter between the baseline and the follow-up studies in 12 patients (two-paired t test). Clusters significant at  $p < 0.05$  corrected for multiple comparison were observed in the left primary sensory motor cortex (two axial views passing at z coordinates of 70 and 76).