

QUANTITATIVE MRI REVEALS EARLY CARTILAGE DEGENERATION IN ACL-INJURED KNEES

X. Li¹, D. Kuo², K. Shet², C. Stehling², J. Cheng², T. Link², B. Ma², and S. Majumdar²

¹Radiology, University of California, San Francisco, San Francisco, CA, United States, ²University of California, San Francisco

INTRODUCTION The anterior cruciate ligament (ACL) rupture is one of the most common and severe knee injuries, and has shown to be a risk factor of post-traumatic osteoarthritis (OA) despite ACL reconstruction (1). Magnetic resonance imaging (MRI) has been used widely for detecting and monitoring joint injuries. Conventional MRI, however, is limited to probing primarily morphologic changes of the joint. Recent developments of quantitative MRI techniques, such as T1ρ and T2 relaxation time quantification, have the potential to provide information about early cartilage degeneration during OA (2-4). This ability of early diagnosis will enable early intervention, and will provide guidance and critical evaluation for new therapeutic strategies. However, there are very limited studies of applying quantitative MRI in evaluating cartilage matrix in acutely injured knees. The goals of this study were: 1) to longitudinally evaluate cartilage matrix changes using T1ρ and T2 quantification, and 2) to study the relationship between meniscal damage and cartilage degeneration in ACL-injured and reconstructed knees.

METHODS

Twelve patients with acute ACL injuries (7 male, mean age = 34 years, range = 27-45 years) and 10 healthy volunteers (7 male, mean age = 34 years, range = 19-57 years) were scanned with a 3T GE MR scanner using a transmit/receive quadrature knee coil. Patients were initially scanned prior to surgery within 4 weeks of injury and subsequently at 1-year post surgery. The imaging protocol included sagittal T2-weighted fast spin-echo (FSE) images (matrix = 512×256, FOV = 16cm, slice thickness = 2mm), sagittal 3D water excitation high-resolution spoiled gradient-echo (SPGR) images (matrix = 512×512, FOV = 16cm, slice thickness = 1mm), and T1ρ and T2 quantification sequences based on 3D SPGR previously developed in our lab (FOV = 14cm, slice thickness = 4mm, for T1ρ: time of spin-lock = 0/10/40/80 ms, spin lock frequency = 500Hz; for T2: TE = 4.1, 14.5, 25, 45.9ms) (5). Cartilage of the lateral/medial femoral condyles (LFC/MFC) and the lateral/medial tibia (LT/MT) were segmented semi-automatically in the SPGR images using an in-house developed software (6), and were further divided into sub-compartments with regard to meniscus (Fig 1). T1ρ and T2 maps were reconstructed by fitting the T1ρ- and T2-weighted images pixel-by-pixel and were subsequently aligned to their SPGR images. T1ρ and T2 values of each sub-compartment were obtained. A Student's t-test was used to compare T1ρ and T2 values between patients and controls in matched sub-compartments. The radiographs were graded using KL scores by a musculoskeletal radiologist. Cartilage lesions, osteophytes and meniscal damages were also assessed using a modified Whole-Organ Magnetic resonance imaging Score (WORMS) (7). Specifically, the anterior and posterior horns of each of the lateral and medial menisci were graded from 0 to 4 based on the sagittal T2-weighted FSE fat-saturated images, with 0 = intact menisci, 1 = signal abnormality, 2 = non-displaced tear or prior surgical repair, 3 = displaced tear or partial resection, and 4 = complete maceration / destruction or complete resection.

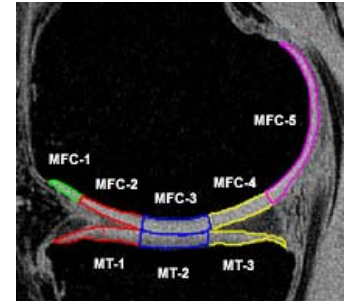


Fig. 1 Sub-compartment definition (using medial side as an example).

RESULTS

One patient had radiograph KL = 1 and all others had KL = 0. Based on MRI: 2 patients showed osteophytes; 2 patients had cartilage focal lesions in patella, 3 had in MFC and 1 had in LFC; 8 patients show meniscal lesions and all lesions were in posterior horns: 6 in medial menisci and 6 in lateral menisci (2 patients had lesions in both lateral medial menisci).

In the lateral side, LT-3 had significantly higher T1ρ at baseline ($P < 0.05$) and at 1-year follow up (with margin significance $P = 0.07$) compared to knees from healthy controls. No significant elevation of T2 was observed in lateral side for both time points except for baseline T2 elevation in LT-3 reached margin significance ($P = 0.06$). In the medial side, no significant elevation of T1ρ or T2 was observed at baseline. At 1-year follow up, T1ρ values in MFC-2, MFC-3 and MT-2 were elevated significantly compared to controls ($P < 0.05$), with an increase percentage of 11.1%, 14.9% and 13.0% respectively, Fig 2. Significantly increased T2 was observed in MFC-2 at 1-year follow up ($P < 0.05$) with an increase percentage of 11.7%, but not in MFC-3 and MT-2.

Based on meniscal lesions in medial side, we grouped the 12 patients into two groups: group I with lesions in posterior horn of medial meniscus ($n = 6$, # of grade 1, 2, 3, 4 = 3, 1, 1, 1), and group II with no tear in this region ($n = 6$). Patients in group I (with lesions) showed a higher T1ρ increase from baseline to 1-year follow up in MFC-3 and MFC-4 compared to those without lesions in this region (in MFC-3 for example, 35.4 ± 6.8 ms at baseline and 41.7 ± 3.3 ms at 1-year follow up for patients with lesions, 35.1 ± 5.6 ms at baseline and 36.6 ± 5.7 ms at 1-year follow up for patients without lesions). No such correlation was found in lateral side.

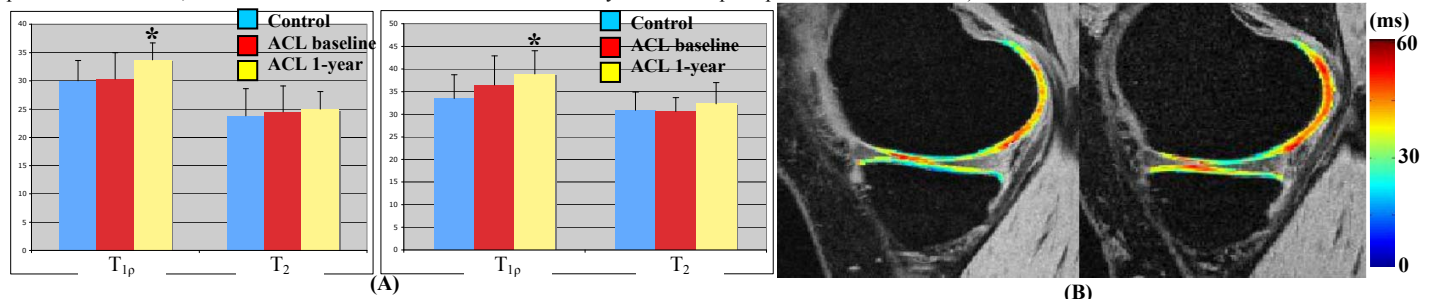


Fig. 2 (A) Cartilage T1ρ and T2 values (in ms) in MT-2 (left) and MFC-3 (right) sub-compartments. (* $P < 0.05$ compared to controls) (B) T1ρ maps of the medial side of an ACL-injured knee at baseline (left) and 1-year post ACL reconstruction (right).

DISCUSSION AND CONCLUSIONS Quantitative MRI can detect changes in cartilage composition as early as 1 year post ACL reconstruction, in particular in the contacting areas of MFC and MT. Data from this small cohort suggested that T1ρ is more sensitive than T2 in detecting early degeneration in ACL-injured knees. This may be explained by that spin-lock techniques applied in T1ρ quantification reduce dipolar interactions and therefore reduce the dependence of T1ρ on collagen fiber, as compared to T2, and increase the sensitivity for detecting proteoglycan loss. LT-3 is the subcompartment that is overlying the typical bone bruise in LT. Interestingly, elevated T1ρ values in LT-3 were observed at both baseline and 1-year follow up, despite resolution of bone bruise, suggesting potential irreversible damage in these regions. Our preliminary data also show that, if there is a lesion in the posterior horn of medial meniscus, the cartilage contacting this area (MFC-3 and MFC-4) may have an accelerated degeneration. This result implies that meniscal lesions play an important role during joint degeneration in ACL-injured knees.

REFERENCES 1. Lohmander et al., Arthritis Rheum 2004; 2. Mosher et al, Radiology; 3. Borthakur et al, NMR Biomed 2006; 4 Li et al, Osteoarthritis Cartilage 2007; 5. Li et al, MRM 2008; 6. Carballido-Gamio et al, Med Image Anal 2008; 7. Peterfy et al, Osteoarthritis Cartilage 2004.

ACKNOWLEDGEMENTS: This research was supported by Aircast Foundation, NIH K25 AR053633 and RO1 AR46905.